

<https://doi.org/10.31288/oftalmolzh202432427>

## Effect of Neodymium : Yttrium Aluminum Garnet Laser Capsulotomy on Visual Acuity and Contrast Sensitivity in Patients with Posterior Capsular Opacity in a Tertiary Care Hospital

Sushma HK <sup>1</sup>, Ramya M <sup>2</sup>, Sathyendranath Shetty <sup>3</sup>

<sup>1</sup> District Hospital

<sup>2</sup> Chikballapur Institute of Medical Sciences  
Chikballapur (India)

<sup>3</sup> MS Ramaiah Medical College  
Bangalore (India)

### Key words:

posterior capsular opacification (PCO), Nd-YAG capsulotomy, contrast sensitivity, best corrected visual acuity (BCVA), small incision cataract surgery (SICS), posterior chamber intraocular lens (PCIOL)

**Purpose.** This study was conducted to compare the improvement in visual acuity and contrast sensitivity before and after neodymium yttrium aluminum garnet (Nd-YAG) capsulotomy in patients with posterior capsular opacity.

**Materials and Methods.** A prospective study of 72 eyes of 60 patients with posterior capsular opacity (PCO) was conducted in the Department of Ophthalmology after approval from the institutional ethical committee of M S Ramaiah Medical college. A complete ophthalmological examination, including a detailed history, best corrected visual acuity using Snellens chart, and contrast sensitivity (before and after Nd-YAG capsulotomy) using Pelli Robson chart, slit lamp examination, IOP measurement, and fundus examination were performed after obtaining informed consent adherence to the tenets of Declaration of Helkinki.

**Results.** The study comprised 60 patients, age groups ranging from 50 to 96 years, with the mean age of patients in our study being 65.943±8.83 years. BCVA of 62 eyes (86.2%) was between 6/18 and 6/60. After Nd YAG capsulotomy, patients showed great improvement in vision, with 63 eyes (87.5%) having improved BCVA of better than 6/12, and 24 eyes (33.3%) showing BCVA of 6/6 ( $p < 0.001$ ). The contrast sensitivity of 69 eyes (95.83%) was between 0 and 1.65 log units, followed by 3 eyes (4.17%) between 1.80 and 1.95 log units. After Nd-YAG capsulotomy, contrast sensitivity of 61 eyes (84.72%) improved to 1.80 – 2.25 log units, whereas the remaining 11 eyes (15.28%) showed contrast sensitivity of 1.20 – 1.65 log units ( $p < 0.001$ ).

**Conclusion.** Nd-YAG capsulotomy is an effective and relatively safe procedure for the management of posterior capsular opacity. It significantly improves both visual acuity and contrast sensitivity, thereby improving the quality of vision.

### Introduction

Posterior capsular opacification (PCO) remains one of the most common postoperative morbidities in modern day cataract surgery. Nd:YAG posterior capsulotomy is one of the most commonly performed surgical procedures [1, 2].

The incidence of PCO development ranges from 25% to 50%. PCO is caused by the proliferation of lens epithelial cells, which causes fibrotic changes and wrinkling of the posterior capsule. After small incision cataract surgery (SICS), equatorial differentiation of cells into fiber-like structures leads to Sommering's ring formation and peripheral thickening of the capsular bag. Closer to the rhexis margin, cell swelling can result in the formation of globular Elschnig's pearls, which may occlude the visual axis by causing forward and backward light scattering, reducing the visual acuity (VA) and contrast sensitivity (CS). PCO is diagnosed by Slit Lamp examination and Direct/Indirect ophthalmoscopy. Neodymium yttrium aluminum garnet (Nd-YAG) laser therapy presents the advantage of being a non-invasive, effective, and relatively safe technique to

manage intact posterior capsules that opacify postoperatively, and it does not require patient hospitalization.

This study was undertaken to compare and determine the improvement in contrast sensitivity and visual acuity using the Pelli Robson chart and Snellen chart, respectively, before and after Nd-YAG capsulotomy in patients with PCO.

### Materials and methods

This is a prospective interventional study conducted in patients after obtaining informed consent. A minimum of 60 patients with posterior capsular opacity (PCO) attending the Department of Ophthalmology were included in the study after satisfying the inclusion and exclusion criteria. Institutional ethical committee clearance was obtained from M S Ramaiah Medical College.

A complete examination, including a detailed history, general physical examination, best corrected visual acu-

ity (BCVA) (before and after Nd-YAG capsulotomy on the day of capsulotomy, contrast sensitivity (before and after Nd-YAG capsulotomy), slit lamp examination, IOP measurement, and fundus examination (by direct and indirect ophthalmoscopy and slit lamp biomicroscopy using 90D lens), was performed on each included patient. After providing informed consent, the patients were prepared to undergo Nd-YAG capsulotomy using Visulas YAG III by Ziess. After capsulotomy, standard examination including visual acuity, contrast sensitivity, anterior segment-slit lamp examination, intraocular pressure recording, and fundus examination was repeated.

Patients presenting with PCO following cataract surgery with PCIOL implantation with affected vision were included in the study. Patients presenting with any pathology of the cornea, pathology of the vitreous, retina, optic nerve, or affecting vision were excluded from the study.

**Preparation of the patient.** The patient was briefed about the purpose of the procedure, duration, painless nature, and importance of maintaining steady fixation, and written consent was obtained. Pupillary dilation. Dilatation of the pupil was performed with Tropicamide 0.8% and Phenylephrine 5% eye drops. Capsulotomies were performed under topical anesthesia with 0.5% proparacaine.

**Procedure.** The patient was reassuringly introduced to the equipment. The head was gently placed in front of the laser on the chin rest, and a head strap was applied. Contact lenses were used in uncooperative patients. Areas were noted where the lens capsule was thinnest and where the capsule appeared to be under tension. A setting of 0.6 - 2 MJ of power was delivered in the single pulse mode. A circular opening, measuring approximately 3–5 mm, was made in the pupil.

**Post-procedure care.** Timolol 0.5%, 1 drop twice a day for 7 days was administered post-laser to counter post-laser intraocular pressure spike. BCVA and contrast sensitivity were recorded. IOP and examination under a slit lamp were performed immediately within 1- 4 hours of the Nd-YAG capsulotomy procedure.

**Statistical analysis.** All quantitative variables such as age and the time between cataract extraction and PCO development will be summarized using descriptive statistics such as Mean and Standard deviation. All qualitative variables such as PCO, visual acuity, contrast sensitivity, and comorbidities before and after Nd-YAG capsulotomy presented using frequency and percentage. Pre and Post comparisons of contrast. Pre- and post-comparisons of contrast sensitivity and visual outcomes were compared using McNemar's test. Statistical analysis and a P value of < 0.05 was statistically significant. Data analysis was performed using Statistical Package for Social Science (SPSS version 18.0)

## Results

**Age distribution.** The study comprised patients ranging from 50 to 96 years. Fifty percent (30 patients) belonged to the age group of 60 – 70 years, whereas age groups of 50 – 60 and above 70 consisted of 25% (15 patients).

**Gender distribution.** Females were predominant in this study, contributing to 58.3%, and 41.7% of the total patients were males.

**Duration since surgery.** The interval between cataract surgery and Nd-YAG capsulotomy ranged from 4 to 240 months, with 54.2% (39 eyes) reported between 12 and 36 months.

**The type of cataract surgery.** Of the 72 eyes, 73.6% (53 eyes) underwent small incision cataract surgery (SICS), whereas 26.4% (19 eyes) underwent Phacoemulsification surgery.

**BCVA before Nd-YAG capsulotomy.** Of 72 eyes, 86.2% (62 eyes) had BCVA between 6/18 and 6/60. Among the remaining 13.8%, 9.7% (7 eyes) had BCVA Of less than 6/60 and 4.1% (3 eyes) had BCVA of 6/9 to 6/12, as shown in table 1.

**Contrast sensitivity before Nd-YAG capsulotomy.** Out of 72 eyes, the majority of the patients 95.83% (69 eyes) had contrast sensitivity between 0 and 1.65 log units followed by 4.17% (3 eyes) between 1.80 and 1.95 log units, as shown in table 2 .

**BCVA after Nd-YAG capsulotomy.** After Nd-YAG capsulotomy, patients showed improvement in vision, 87.5% (63 eyes) had BCVA of better than 6/12, and 33.3% (24 eyes) had BCVA of 6/6, as shown in table 3. Nine eyes did not improve beyond 6/18 because BCVA was checked on the day of capsulotomy with dilated pupil and slit lamp exposure.

**Contrast sensitivity after Nd-YAG capsulotomy.** After Nd-YAG capsulotomy, patients showed improvement in

**Table 1.** Best corrected visual acuity (BCVA) before Nd-YAG capsulotomy

BCVA	Number of eyes	Percentage
Less than 6/60	7	9.7%
6/36-6/60	31	43.1%
6/18-6/24	31	43.1%
6/9-6/12	3	4.1%
6/6 or better	0	0%

**Table 2.** Contrast sensitivity before Nd-YAG capsulotomy

Contrast sensitivity	Number of eyes	Percentage
0.00-0.15	0	0%
0.35-0.45	1	1.39%
0.60-0.75	17	23.61%
0.90-1.05	3	4.17%
1.25-1.35	24	33.33%
1.50-1.65	24	33...%
1.80-1.95	3	4.17%
2.10-2.25	0	0%

**Table 3.** Best corrected visual acuity (BCVA) after Nd-YAG capsulotomy

BCVA post YAG capsulotomy	Number of eyes	Percentage
Less than 6/60	0	0
6/36-6/60	1	1.4%
6/18-6/24	8	11.1%
6/9-6/12	39	54.2%
6/6 or better	24	33.3%

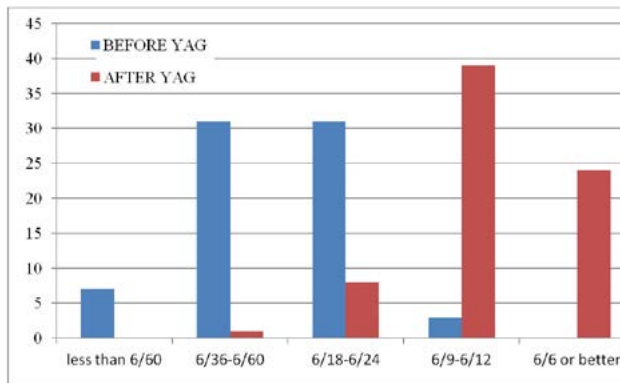
**Table 4.** Contrast sensitivity after Nd-YAG capsulotomy

Contrast sensitivity	Number of eyes	Percentage
0.00-0.15	0	0%
0.30-0.45	0	0%
0.60-0.75	0	0%
0.90-1.05	0	0%
1.20-1.35	1	1.39%
1.50-1.65	10	13.89%
1.80-1.95	24	33.33%
2.10-2.25	37	51.39%

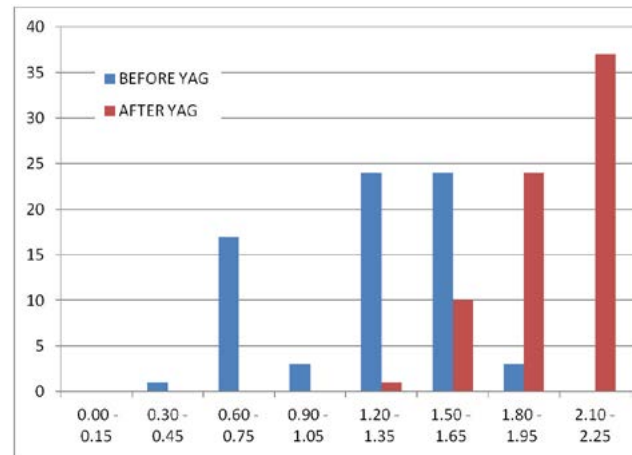
contrast sensitivity. In 84.72% (61 eyes), contrast sensitivity improved to 1.80 – 2.25 log units, whereas the remaining 15.28% (11 eyes) showed contrast sensitivity of 1.20 – 1.65 log units, as shown in table 4.

**BCVA before and after Nd-YAG capsulotomy.** Out of 72 eyes, 86.2% (62 eyes) had BCVA between 6/18 and 6/60. Among the remaining 13.8%, 9.7% (7 eyes) had BCVA Of less than 6/60 and 4.1% (3 eyes) had BCVA of 6/9 to 6/12, and nobody had a vision of 6/6 or better. After Nd-YAG capsulotomy, patients showed significant improvement in vision, 87.5% (63 eyes) showed BCVA of better than 6/12, and 33.3% (24 eyes) had BCVA of 6/6, as shown in the figure 1.

**Contrast sensitivity pattern before and after Nd-YAG capsulotomy.** Out of 72 eyes, majority of the patients



**Figure 1.** BCVA before and after Nd-YAG capsulotomy



**Figure 2.** Contrast sensitivity pattern before and after Nd-YAG capsulotomy

95.83% (69 eyes) had contrast sensitivity between 0 and 1.65 log units followed by 4.17% (3eyes) between 1.80 and 1.95 log units. After Nd-YAG capsulotomy, patients showed improvement in contrast sensitivity. In 84.72% (61 eyes), contrast sensitivity improved to 1.80–2.25 log units, whereas the remaining 15.28% (11 eyes) showed contrast sensitivity of 1.20–1.65 log units, as shown in figure 2.

**Discussion**

Posterior capsular opacification (PCO) is the most common complication of cataract surgery, occurring in up to 50% of patients after 2–3 years of surgery. There is an age-related tendency toward PCO formation; the incidence of PCO is almost 100% in pediatric and young individuals and gradually decreases as age advances [3, 4].

This study enrolled 60 patients (72 eyes) of age groups ranging from 50 to 96 years. The maximum number of patients belonged to the age group between 61 and 70 years, which included 30 patients (50%). The mean age of patients in our study was 65.943±8.83 years. Das et al. found the mean age to be 59.08±5.84 years [5], whereas Joshi et al. found the mean age of group A patients was 61.65±8.85 years. [6]

In the present study, we found that the incidence of laser capsulotomy was much higher among females, which included 35 cases (58.3%), than among males, which included 25 cases (41.7%). Male-to-female ratio is 1:1.4. Das et al. found that the incidence of laser capsulotomy was much higher among males, which included 20 cases (40%), than among females, which included 30 cases (60%). [5].

In the present study, out of 72 eyes studied, 53.3% (32 eyes) were right eye and 26.6% (16 eyes) were left eye, whereas 20% (12 patients) had PCO in both eyes. In this study, we found that the time interval between the development of PCO after cataract surgery ranged from 4 to 240 months.

Takkar et al. showed that the average period between cataract extraction and Nd-YAG laser capsulotomy as 45.58±37.33 months. [7]. In our study, the pre-laser best

corrected visual acuity ranged from 1/60 to 6/12. Out of 72 eyes, 95.9% (69 eyes) had BCVA between 1/60 and 6/18 and 4.1% (3 eyes) had BCVA between 6/9 and 6/12, and nobody had a vision of 6/6 or better. After Nd-YAG capsulotomy, the improvement in visual acuity was significant; 87.5% (63 eyes) had BCVA of better than 6/12 out of which 33.3% (24 eyes) had BCVA of 6/6, which was statistically significant ( $p < 0.001$ ). Only 9 patients had a BCVA of less than 6/18, out of which only 1 patient had a BCVA of 6/36. However, there was no further deterioration of VA in any case

A study conducted by Mishra et al. in 184 patients found that Visual acuity improved to 6/6 in 40 (21.73%) cases, 6/9 in 67 (36.41%) cases, and 6/12 in 29 (15.21%) cases. [8]. Only 3 (3%) patients had visual acuity improved to less than 6/24. Out of 3 patients, 1 patient had visual acuity improved to 6/60 and 2 had improved to 6/36.

Wakamatsu et al. studied patients who were treated with Nd-YAG capsulotomy and found a significant improvement in the mean functional visual acuity, from  $0.18 \pm 0.11$ . [9]

After capsulotomy mean visual acuity, contrast sensitivity, and glare sensitivity improved significantly ( $p < 0.001$ ). Yotsukura et al. found that the mean corrected distance visual acuity (CDVA) low contrast visual acuity (LCVA) after Nd:YAG laser capsulotomy improved significantly ( $p < 0.05$ ). [10].

These studies were by our study, whereby contrast sensitivity is shown to significantly improve after Nd YAG laser capsulotomy. A transient rise in IOP and IOL pitting were the most common complications noted after Nd-YAG capsulotomy, which did not cause any deterioration of vision. In our study, no patient had a decrease in visual acuity compared with pre-laser visual acuity in any case. Vision was improved in all patients by at least one line improvement in Snellen's chart along with improvement in contrast sensitivity.

### Conclusion

Posterior capsular opacification (PCO) is the most common long-term complication of cataract surgery, with PCIOL implantation occurring in up to 50% of patients after 2–3 years of surgery. Nd-YAG capsulotomy is an effective and relatively safe procedure for the management of posterior capsular opacity. It significantly improves both visual acuity and contrast sensitivity, thereby improving the quality of vision.

### References

1. Spalton DJ. Posterior capsular opacification after cataract surgery. *Eye*. 1999;13:489–492.
2. Bertelmann E, Kojetinsky C. Posterior capsule opacification and anterior capsule opacification. *Curr Opin Ophthalmol*. 2001;12:35–40.
3. Pande MV, Ursell PG, Spalton DJ, Heath G, Kundaiker S. High-resolution digital retroillumination imaging of the posterior lens capsule after cataract surgery. *J Cataract Refract Surg*. 1997 Dec;23(10):1521-7. doi: 10.1016/s0886-3350(97)80023-5.
4. Schaumberg DA, Dana MR, Christen WG, Glynn RJ. A systematic overview of the incidence of posterior capsule opacification. *Ophthalmology*. 1998 Jul;105(7):1213-21. doi: 10.1016/S0161-6420(98)97023-3.
5. Das N, Shams A, Khan B, Kumar J, Nasir S, Bhatti NM. Effects of Neodymium-Doped Yttrium Aluminium Garnet (Nd:YAG) Laser Capsulotomy on Visual Outcomes From a Lower-Middle Income Country. *Cureus*. 2021 Sep 11;13(9):e17895. doi: 10.7759/cureus.17895.
6. Joshi Rajesh S; Doble Pallavi. The complication rate following Neodymium-doped Yttrium Aluminum Garnet laser posterior capsulotomy for posterior capsular opacification in patients with and without comorbidities. *Indian Journal of Ophthalmology* 71(3):p 791-796, March 2023. doi: 10.4103/ijo.IJO\_1885\_22
7. Takkar B, Chandra P, Temkar S, Singh AK, Bhatia I. Predictors of Successful Laser Capsulotomy for Significant Posterior Capsule Opacification after Phacoemulsification. *J Ophthalmic Vis Res*. 2017 Apr-Jun;12(2):170-174. doi: 10.4103/jovr.jovr\_244\_15.
8. Sahu P, Mishra AK. Safety and efficacy of Nd:YAG laser capsulotomy in management of posterior capsular opacification. *Int J Adv Med* 2019;6:76-80.
9. Wakamatsu, Tais Hitomi MD; Yamaguchi, et al. Functional visual acuity after neodymium:YAG laser capsulotomy in patients with posterior capsule opacification and good visual acuity preoperatively. *Journal of Cataract & Refractive Surgery* 37(2):p 258-264, February 2011. doi: 10.1016/j.jcrs.2010.08.048
10. Yotsukura Erisa, Torii, Hidemasa, Saiki Megumi, Negishi Kazuno, Tsubota Kazuo. Effect of neodymium:YAG laser capsulotomy on visual function in patients with posterior capsule opacification and good visual acuity. *Journal of Cataract & Refractive Surgery* 42(3):p 399-404, March 2016. doi: 10.1016/j.jcrs.2015.11.042

### Disclosures

Received: 24.02.2024

Accepted: 30.05.2024

**Author's contribution:** Sushma HK – conceptualisation, data collection, data analysis, manuscript preparation and review; Ramya M – conceptualisation, data collection, data analysis, manuscript preparation and review; Sathyendranath Shetty – conceptualisation, manuscript preparation and review.

**Financial support:** no financial support received.

**Conflict of interest statement:** None of the following authors have any proprietary interests or conflicts of interest related to this submission. This submission has not been published anywhere previously and is not simultaneously being considered for any other publication.

**Disclaimer:** The opinions presented in this article are those of the authors and do not necessarily represent those of their institutions.