

<https://doi.org/10.31288/oftalmolzh202326062>

### An unusual case of posterior vitreous detachment

Bruno Barbosa Ribeiro <sup>1</sup>, João Oliveira Leite <sup>1</sup>, Miguel Mesquita Neves <sup>1</sup>, Angelina Meireles <sup>1,2</sup>

<sup>1</sup> Department of Ophthalmology, Centro Hospitalar Universitário do Porto

<sup>2</sup> Instituto de Ciências Biomédicas Abel Salazar (ICBAS) Oporto (Portugal)

**Key words:**

macular microhole; posterior vitreous detachment

*Purpose:* To describe a case of spontaneous closure of a macular microhole induced by an acute posterior vitreous detachment (PVD).

*Methods:* Retrospective case report and analysis of patient data.

*Case Report:* We present a case of spontaneous closure of a posterior vitreous detachment (PVD) induced macular microhole. In our patient, macular microhole developed a few weeks after acute PVD. The development of macular hole secondarily to acute PVD is rare, and there are reports of spontaneous closure. Reporting this case is important to alert clinicians to the potential self-resolving nature of this pathology.

*Conclusion:* Macular hole is a rare complication of acute PVD. Some cases resolve spontaneously without the need for surgical correction. A conservative approach may be an appropriate setting if no high-risk features are present.

#### Introduction

Posterior vitreous detachment (PVD) refers to the separation of the posterior vitreous cortex from the retina's internal limiting membrane (ILM) and is the most common cause of floaters. Although statistics are lacking, its onset is typically in the sixth decade, and prevalence increases with age and axial length. [1, 2].

It is thought to occur abruptly and secondarily to a tear in the posterior hyaloid, with liquified vitreous gaining access to the subhyaloid space, promoting separation of the posterior hyaloid from the ILM. It begins posteriorly and extends to the vitreous base. The most common complications result from anomalous vitreoretinal traction and include retinal tears, vitreous hemorrhage, rhegmatogenous retinal detachment and retinal hemorrhage. Rarely, it can result in macular hole formation and cystoid macular edema. [3].

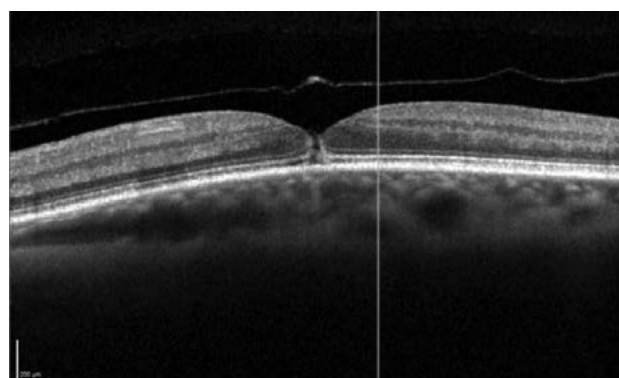
We report a case of spontaneous closure of a macular microhole secondary to PVD.

#### Case summary

A 70-year-old female presented to the emergency department due to floaters in the left eye for 5 days. She denied photopsias or any “shades” or “curtains” in her peripheral vision. There was no history of trauma. The patient's past ophthalmologic history was unremarkable. She had a best-corrected visual acuity (BCVA) of 20/40 in her left eye and 20/20 in her right eye. There was no relative afferent pupillary defect, and ocular motility was normal. On slit-lamp examination, there were no pathological changes in the anterior segment except for nuclear cataract. Applanation tonometry was 16 mmHg. On dilat-

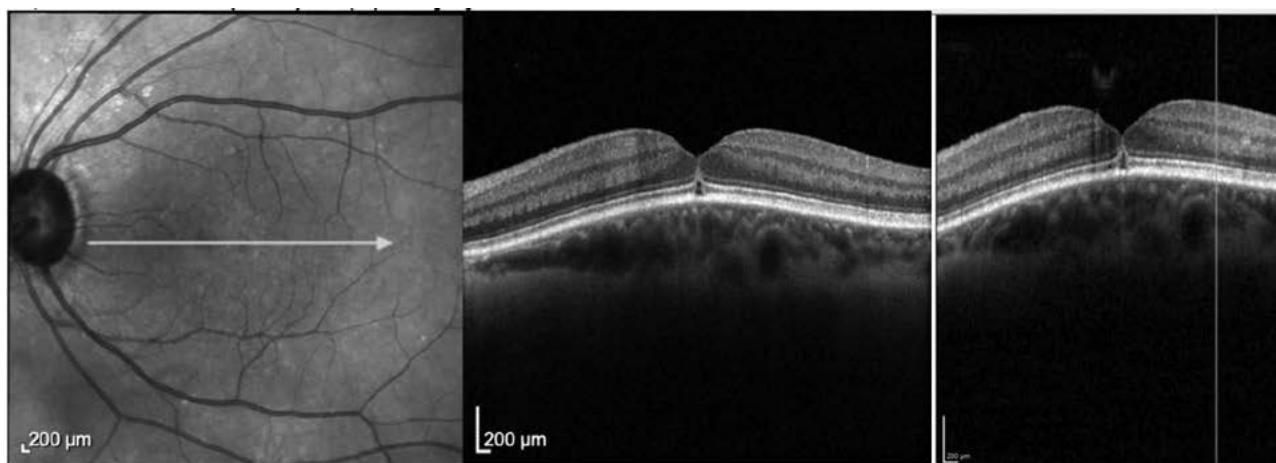
ed funduscopy examination, there was vitreous syneresis and an incomplete Weiss ring. Retinal periphery revealed no holes, tears, or subretinal fluid on 360-degree Goldmann 3-mirror lens examination. There was an absent foveal reflex.

Optical Coherence Tomography (OCT) demonstrated a PVD with a macular microhole (figure 1). The patient was referred to a vitreoretinal surgeon. Given the recent onset, preservation of visual acuity, and very small size of the hole, a conservative approach was decided and the patient was to return in 1-week. At 1-week appointment, the OCT showed a closing macular microhole with sub-

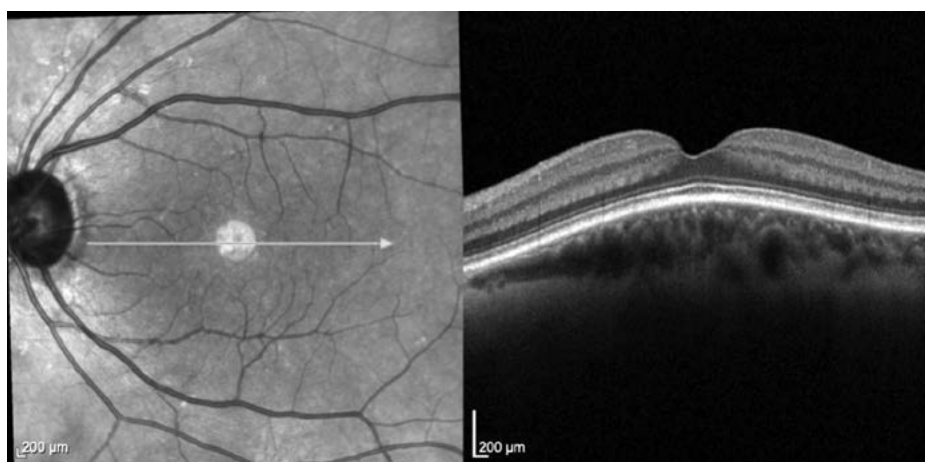


**Figure 1.** Macular microhole secondary to acute PVD at initial presentation

© Bruno Barbosa Ribeiro, João Oliveira Leite, Miguel Mesquita Neves, Angelina Meireles, 2022



**Figure 2.** Spontaneous closure of macular microhole



**Figure 3.** Spontaneous closure of macular microhole at last follow-up

retinal fluid. After 1 month, the patient reported reduction in floaters and presented with a BCVA of 10/10. The OCT showed complete closure of the macular microhole (figures 2 and 3).

### Discussion

A macular hole is a vitreoretinal pathological entity characterized by a partial or full thickness defect in the neurosensory retina in the fovea. It may present as metamorphopsia or central scotoma. It may be idiopathic, traumatic, or myopic. [4, 5].

Its pathophysiology differs: while idiopathic macular hole is associated with dynamic traction caused by the posterior cortical vitreous, traumatic macular hole is thought to arise due to foveal photoreceptor atrophy following commotio retinae. On the other hand, more complex mechanisms may be involved in the development of myopic macular hole. [4-6].

Current treatment options include pars plana vitrectomy with PVD induction, ILM peeling (with or without an inverted ILM flap technique), and endotamponade, with high anatomic success rates. [4, 5].

The term macular microhole has been described by Cairnes and McCombe [6] and is a different nosological

entity. There have been reported associations with trauma and vitreoretinal interface diseases, and it may be misdiagnosed as solar maculopathy. [7]. It is rarely associated with posterior vitreous detachment, and its pathology is thought to arise due to abnormal vitreoretinal physics with antero-posterior vitreous traction and subsequent central foveal avulsion. [7]. Typically, these patients are found to have stage 2 PVD overlying a small (50 to 150 µm) full-thickness macular hole with no remaining vitreoretinal traction. These may resolve spontaneously in some weeks without the need for surgical intervention. [3].

Therefore, it should also be noted that a macular microhole should be differentiated from a Gass stage 2 macular hole – the former presents with sudden onset of symptoms, followed by improvement or stabilization, both anatomically and functionally, while the latter is characterized by subacute onset of symptoms with worsening as the hole develops. Also, macular holes typically present with flattening of the foveal concavity and may not show signs of posterior vitreous detachment. [8].

OCT imaging is crucial in the diagnosis of this entity, as it may reveal small, full-thickness foveal defect with flat edges and no residual vitreous attachment, the detached posterior hyaloid, small defects in the photoreceptor layer,

and the presence of retinal fluid. Lai et. al. [9] have reported a similar case illustrated by OCT. Thus, we consider that our case contributes to the description of this underdiagnosed entity by mean of Spectral-Domain OCT and supports the hypothesis of natural closure.

### Conclusion

Macular microhole is a rare but underdiagnosed complication of acute PVD. OCT is a crucial tool in its diagnosis. Despite the lack of statistics, some cases resolve spontaneously without the need for surgical correction. Thus, in the appropriate scenario, a conservative approach may be suitable for some patients.

### References

1. **Ahmed F, Tripathy K.** Posterior Vitreous Detachment. StatPearls Publishing; 2022. Accessed December 18, 2022. <https://www.ncbi.nlm.nih.gov/books/NBK563273/>
2. **Ramovecchi P, Salati C, Zeppieri M.** Spontaneous posterior vitreous detachment: A glance at the current literature. *World J Exp Med.* 2021;11(3):30-36.
3. **Johnson MW.** Posterior vitreous detachment: evolution and complications of its early stages. *Am J Ophthalmol.* 2010;149(3):371-382.e1.
4. **Majumdar S, Tripathy K.** Macular Hole. StatPearls Publishing; 2022. Accessed December 18, 2022. <https://www.ncbi.nlm.nih.gov/books/NBK559200/>
5. **Azzolini C.** Macular Hole: From Diagnosis to Therapy. *J Ophthalmol.* 2020;2020:1473763.
6. **Cairns JD, McCombe MF.** Microholes of the fovea centralis. *Aust N Z J Ophthalmol.* 1988;16(2):75-79.
7. **Zambarakji HJ, Schlottmann P, Tanner V, Assi A, Gregor ZJ.** Macular microholes: pathogenesis and natural history. *Br J Ophthalmol.* 2005;89(2):189-193.
8. **Reddy CV, Folk JC, Feist RM.** Microholes of the macula. *Arch Ophthalmol.* 1996;114(4):413-416.
9. **Lai MM, Bressler SB, Haller JA.** Spontaneous resolution of macular microhole. *Am J Ophthalmol.* 2006;141(1):210-212.

### Disclosures

*Received 30.01.2023*

*Accepted 27.02.2023*

**Corresponding author:** Bruno Barbosa Ribeiro – [brunot.barbosaribeiro@gmail.com](mailto:brunot.barbosaribeiro@gmail.com)