

<https://doi.org/10.31288/oftalmolzh202316767>

Periocular basal cell carcinoma of the eyelids – review

Z. Prídavková^{1,2}, A. Furdová¹, K. Benca Kapitánová², R. Vida²,
P. Žiak^{1,2,3}, I. Popov¹

¹Comenius University, Faculty of Medicine, Dept. of Ophthalmology Bratislava (Slovak republic)

²UVEA Medikliník s.r.o. Martin (Slovak republic)

³Comenius University in Bratislava, Jessenius Faculty of Medicine, Eye Clinic Martin (Slovak republic)

Keywords:

periocular tumours, nonmelanoma skin cancer, basal cell carcinoma, Mohs surgery, vismodegib

Introduction. Basal cell carcinoma is the most common tumour of the eyelids and periocular region throughout the world. BCC represents 90 % of malignant tumours of the eyelids, predominantly in the male population. The incidence is higher in age over 60. Over 50% of BCC of the periocular region initially occur on the lower lid and inner angle.

Research objectives. Literature review of the epidemiology, aetiopathogenesis, clinical attributes, diagnostics, treatment histopathology, recurrence, prognostic factors, and management of BCC.

Core of work. Standardised incidence of diagnosis C44 in the period 1997–2012 in Slovakia ranged from 35.05 to 73.9 cases per 100,000 inhabitants. The histopathological examination is essential. The first consideration for treatment of periocular BCC is radical surgical excision using Mohs micrographic technique. We can consider the apoptotic index, the expression of Bcl-2, as an unexplained prognostic factor of BCC recurrence.

Conclusion. Increased attention must be given to periocular malignant tumours. Functional and aesthetic outcome in patients is important after clear excisions and reconstruction should be carefully considered. Radical exenteration is considered in the case of orbital invasion of high-risk aggressive BCC.

Introduction

Non-melanoma skin tumours (NMSC) are the most widespread malignancies in the Caucasian population, with 18–20-times higher incidence than malignant melanoma and representing 5–10% of all skin tumours. [1]. The most common skin cancer is the basal cell carcinoma (BCC). Over 75% percent of BCC occur in the head and neck region. At about 20% of BCC appear in periocular region. The age of BCC is typically in patients over 60 years. [2, 3]. It arises from pluripotent cells localised in the stratum basale of the epidermis and in the area of the outer hair sheath. Squamous cell carcinoma (SCC) is a much less common but more aggressive tumour than BCC, with eventual metastases into regional lymph nodes. [4]. Orbital invasion is uncommon with a reported incidence about 2%. [5]. BCC of the eyelids has a high risk of recurrence, especially in infiltrative types. They can invade the orbit region and lead to the probability of radical exenteration. The orbital invasion of BCC is in 2–4% and the risk factors include large size of the primary tumour also multiple recurrences, infiltrative histological subtype, perineural spread, the medial canthus and inner angle localization and patient's age over seventy. In less than 1% of basal cell carcinomas perineural invasion is present. [6, 7]. The primary treatment modality for BCC is surgical resection. [8–10].

Core of work

Epidemiology

Nowadays it is impossible to collect the data from cancer registries that would analyse BCC worldwide. We

analysed data of 68,516 patients with dg.C44. in the period 1997–2012. The standardised incidence ranged from 35.05 to 73.9 cases per 100,000 inhabitants. The development of the incidence of clinical stages of malignant skin tumours in the period from 2000–2012, regardless of age. Standardised mortality ranged from 0.2 to 0.9 cases per 100,000 population. Specific data on the diagnosis of C44.1 (Malignant tumour of the skin of the eyelid, including the canthus – the third position of the C44 reporting code) cannot be obtained (NCR 2022). The first data on the detected disease are in the age category of 10–14-year-olds. The incidence then gradually increases up to the maximum in the age category of 70–74-year-olds. Age-specific incidence (or mortality) is the number of cases per 100,000 patients in a given age category and shows a rising tendency for the monitored diagnosis (Fig. 1).

Approximately 40% of patients who have had one BCC will develop another lesion within five years, although the probability of developing a subsequent BCC following the first BCC is significantly less than after a next BCC (12.8% versus 33.9% percent in first year; 20% versus 51.8% in 2 year interval and 34.6% versus 75% in 5 year interval). [11].

The aetiology is linked mainly to exposure to UV radiation in people with pale skin. This fact is founded on extensive studies conducted in Europe, Australia and North America. [1, 12 - 14]. UV radiation produces DNA

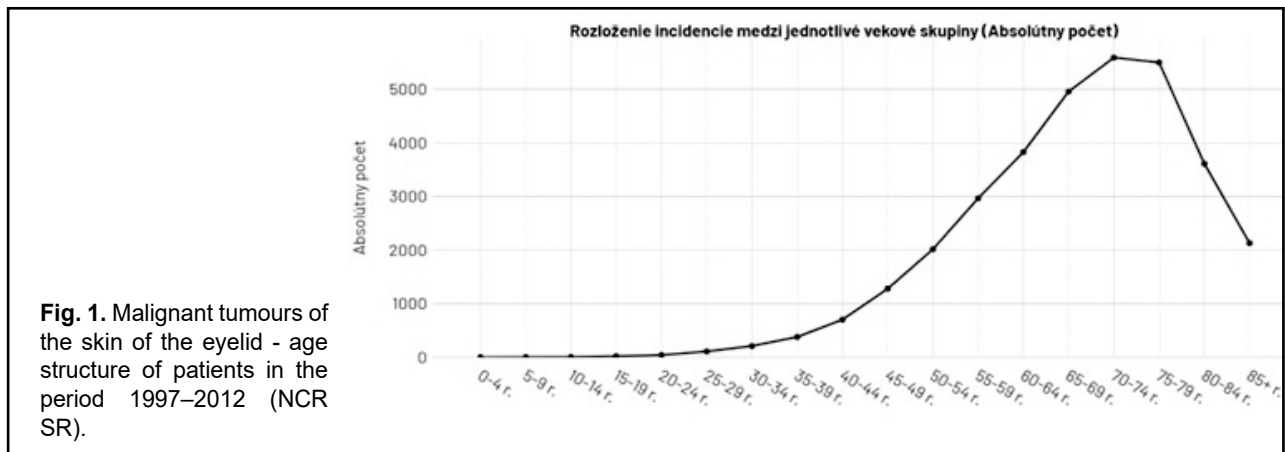


Fig. 1. Malignant tumours of the skin of the eyelid - age structure of patients in the period 1997–2012 (NCR SR).

damage (formation of cyclobutane pyrimidine dimers), gene mutations, immunosuppression, oxidative stress and inflammatory responses, all of which have an important role in photoaging of the skin and skin cancer. In addition to this, UV radiation creates mutations to p53 tumor suppressor genes; these are genes which are involved in DNA repair or the apoptosis of cells that have lots of DNA damage. Therefore, if p53 genes are mutated, they will no longer be able to aid in the DNA repair process; as a result, there is “dysregulation of apoptosis, expansion of mutated keratinocytes, and initiation of skin cancer.” UVA radiation has an important role in the carcinogenesis of stem cells of the skin. UVB radiation induces DNA damage, which causes inflammatory responses and tumorigenesis. [15]. In skin carcinogenesis the mutations play a significant role by activating hedgehog intercellular signaling pathway genes. Patched Ptc-1 mutations promote the development of eyelid BCC. [16, 17]. Viral oncoprotein E6 from beta HPV has the ability to bind to the p53 protein and inactivate it, which results in limiting the induction of apoptosis of cells damaged by UV radiation through the reduction of the pro-apoptotic protein

Bcl-2. Oncoprotein E7 interferes with p16, and these mechanisms lead to an accumulation of mutations and oncogenic transformation of keratinocytes, which are more sensitive to UV-induced carcinogenesis. [18].

Risk factors of multiple BCC are important; the high-risk patients have to be followed up for recurrence or development of new lesions and they have to examine their skin regularly. [19].

There are many factors as risk factors of multiple BCC development. In several studies, a demonstrable dependence between sex, age and the incidence of BCC can be seen. This occurs most often in patients in the sixth to eighth decade of life, with a median age of 62 years (46% were at least 65 years old). A moderate predominance occurs in the male population; i.e. 61% is male. The relationship of the sex of patients to the risk of BCC recurrence is still controversial. In Silverman’s studies, no relationship between sex and tumour recurrences was evident. [19 - 24]. Important are severe actinic damage [25], history of previous radiotherapy [26], increased numbers of identified tumours already present [26 - 28], tumour size over 1 cm [29], lesions on trunk [30-32], positive family his-

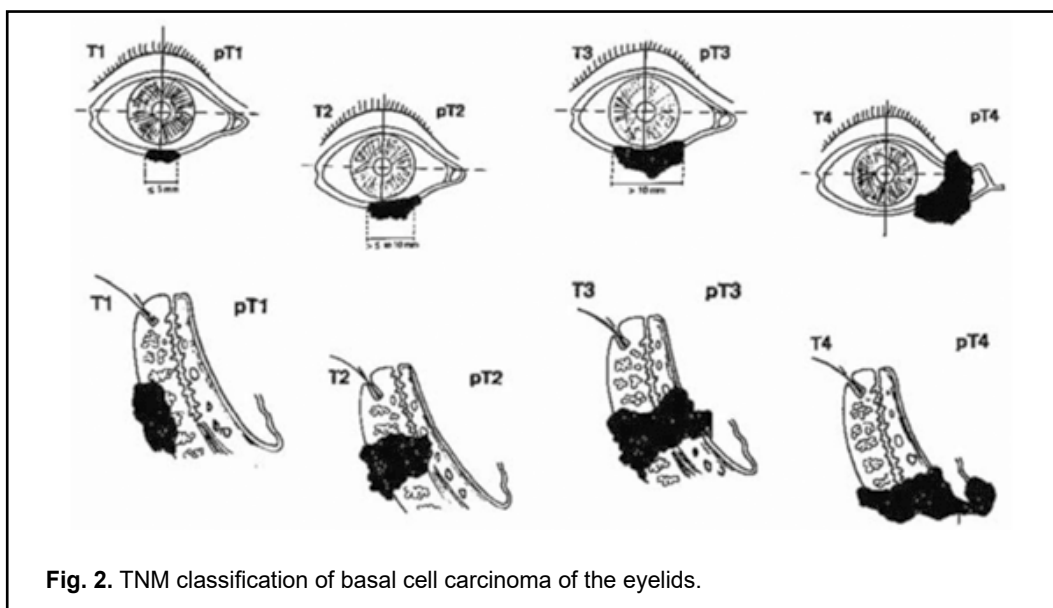


Fig. 2. TNM classification of basal cell carcinoma of the eyelids.

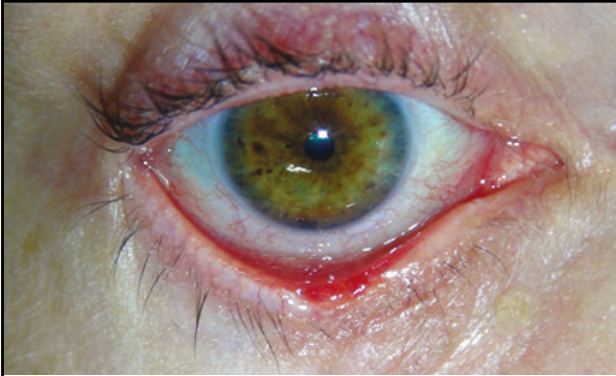


Fig. 3. Basal cell carcinoma of the lower eyelid – subtle manifestation.

Photo: Peter Žiak, Archive of Eye Clinic, Jessenius Faculty of Medicine, Comenius University in Bratislava, Martin

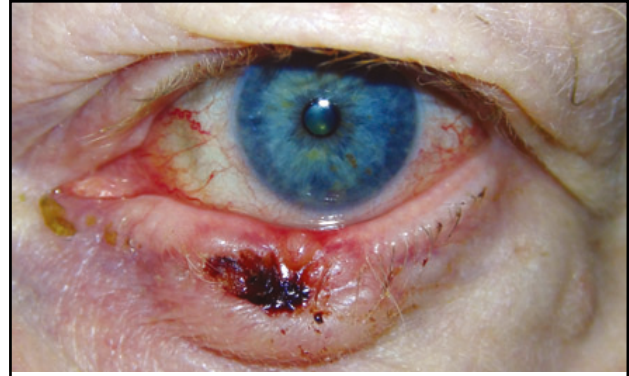


Fig. 4. Basal cell carcinoma of the lower eyelid - ulceration with bleeding.

Photo: Peter Žiak, Archive of Eye Clinic, Jessenius Faculty of Medicine, Comenius University in Bratislava, Martin

tory of other skin tumours [33] low DNA repair capacity [34] detected tumour necrosis factor (TNF), microsatellite polymorphism [35], PTCH gene polymorphism [36] and glutathione S-transferase and cytochrome P450 polymorphism [23, 37].

Classification

For determining the stage of advancement of a tumour, the TNM “staging” classification is used, as well as determining the histopathological degree of “grading” differentiation. Grading is based mainly on the cytological characteristics of the tumour, whereby we distinguish 4 grades: differentiated (G1), moderately differentiated (G2), poorly differentiated (G3) and anaplastic (G4). The classification and stages of basal cell carcinoma in the eyelid region are shown in Fig.2.

Clinical features

More than 50% of the BCCs appear on the lower eyelid, 30% on the medial canthus, 15% on the upper lid and 5% on the lateral canthus. [4]. The clinical manifestations of BCC are diverse. It is most often expressed as erythema, induration, a palpable lesion, recurrent bleeding, or a cystic nodule (Fig. 3, 4, 5). Patients are often without symptoms and without subjective problems [38]. BCC with orbital invasion occur more frequently in the medial canthus (average 60%) compared to the lower eyelid (average 30%), upper eyelid (average 6%) or lateral canthus (average 14%). [39 - 48].

Nodular BCC (50–80%) is the most common type of BCC. It manifests as a slowly growing greyish-white, shiny papule to skin-coloured nodule with a thinned epidermis and telangiectasias. Cystic BCC is often a multilobular lesion made up of transparent nodules with telangiectasias. Both are considered to be low-risk forms of BCC. Superficial BCC (10–30%) (multicentric basal cell carcinoma) are easily infiltrated brown-red lesions, with fine peeling or scabs on the surface; the epidermis in the extent of the tumour lesion has an atrophic appearance. Among the high-risk subtypes of basal cell carcinoma is sclerodermiform BCC (6–10%) – morphea-like basal cell

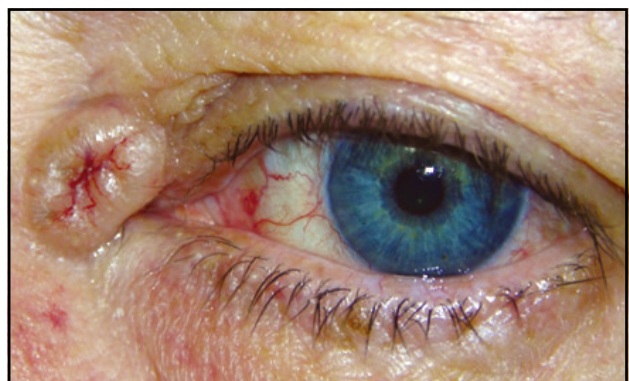


Fig. 5. Basal cell carcinoma of the medial canthus.

Photo: Peter Žiak, Archive of Eye Clinic, Jessenius Faculty of Medicine, Comenius University in Bratislava, Martin

carcinoma. It can grow deep into the dermis and spread perineurally. This type of basal cell carcinoma rarely ulcerates. Infiltrative BCC (5% of cases) is a locally destructive aggressive subtype with a higher risk of local recurrence, and Micronodular BCC (14–15%) is an aggressive and locally destructive subtype with subclinical spread and a higher risk of recurrence. Basal squamous cell carcinoma (so-called metatypical carcinoma) is a tumour that includes mixed regions with typical basaloid differentiation and regions approaching squamous cell carcinoma. [18, 43, 44] An aggressive, infiltrative type of BCC showed a high expression of an apoptotic gene Bcl-2 and moderate levels of proliferation associated markers - proliferating cell nuclear antigen. [44]. It was found that telomere length was shortened and gene expression correlated with cell proliferation (Bcl-2, Ki-67) was increased in BCC [45].

Treatment of periocular BCC

The primary treatment modality for BCC is surgical resection [44]. With respect to the tumour’s location, tissue-sparing methods are often used, which increase the risk of recurrence [45 - 48]. Margin control is necessary

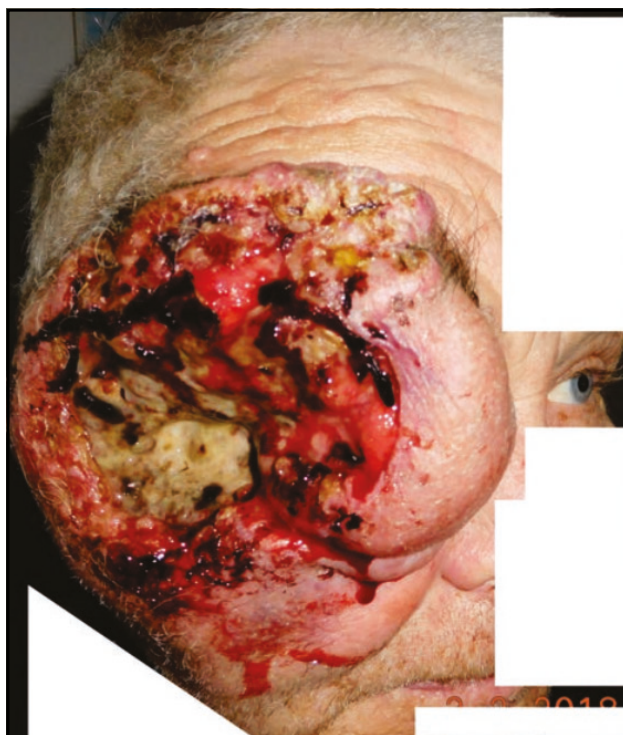

Fig. 6. Patient with large periocular basal cell carcinoma on his right side. According to patients' history tumor started to develop 3 years before from a small lesion in the lower eyelid.

Photo: Alena Furdová, Archive of Dept. of Ophthalmology, Faculty of Medicine, Comenius University.

to achieve clear resection margins to reduce the risk of local recurrence. The recurrence rate after primary surgery is 1%–5% per year [49, 50].

Mohs micrographic surgery has been regarded as the best method of removing BCC with minimal recurrence rate, it is expensive and time consuming and not recommended usually for orbital infiltration due to difficulties by obtaining orientation of specimens from orbital soft tissue. The incidence of recurrence in patients treated without using Mohs micrographic surgery or “en-face” frozen sections intraoperatively ranged from 1.8 to 39%, and the proportion of recurrence increased with longer follow-up of patients. [51–53].

A multidisciplinary team must collaborate in planning management of BCC with orbital invasion (Fig. 6). In many patients orbital exenteration is the approach selected after the failure of previous therapeutic modalities. Given that recurrence after exenteration can be as high as 50–75%, it is very important not to underestimate the timely management of these lesions. Complications can include fistula formations into sinuses, to the nasolacrimal duct, tissue necrosis, chronically exposed bone, cerebrospinal fluid leak, pain or secondary infections. The time interval after exenteration for healing with granulation can occasionally far exceed the usual 3–4 months. Cosmetic defects after exenteration are covered by individual epithesis.

Other treatment modalities

Vismodegib is an available, orally administered specific inhibitor of the Hedgehog pathway with a small molecule. The signalisation of the Hedgehog pathway through the transmembrane protein Smoothened leads to activation and nuclear localisation of Glioma-Associated Oncogene (GLI) transcription factors and the inducing of the Hedgehog target genes. Vismodegib has been approved by the US Food and Drug Administration (FDA) and the European Medicines Agency (EMA) for patients with locally advanced and metastatic basal cell carcinoma that cannot be managed with surgery or radiotherapy. The approved oral dose of vismodegib is 150 mg/day. [54–56]. Vismodegib can be used to treat basal cell nevus syndrome (Gorlin syndrome) in patients not amenable to surgery with multiple cutaneous lesions of the periocular region and head. [54–56]. The results of a pilot phase 2 clinical trial (ERIVANCE) in 104 patients with locally advanced BCC (laBCC) and metastatic BCC (mBCC) showed a response rate of 48% (laBCC) and 33% (mBCC), respectively, and median duration of response of 9.5 and 7.6 months. Median survival for patients with mBCC was 33.4 months. In laBCC, it is possible to discuss neoadjuvant treatment with an Hh inhibitor with the intention of shrinking the lesions, but there is no randomised data to demonstrate a favourable outcome. In a series of 15 patients treated with vismodegib for 3–6 months before surgery, only 1 patient relapsed after 22 months. [61].

Vismodegib in cream form or per os therapy is generally well tolerated. Side effects like alopecia, muscle spasms, fatigue, nausea, decreased appetite, weight loss, dysomnia, or diarrhoea are sometimes the reasons to give up the therapy with vismodegib. Necessity of additional long term studies is required to estimate the risks factors to establish the treatment criteria for periocular BCC. [62].

Local pharmacological treatment, including the immunomodulator imiquimod and 5% 5-Fluoruracil, is less successful and is not yet widely used in localisation near the edge of the eyelid or the outer or inner corner. The principle of PDT (photodynamic therapy) is the accumulation of a photosensitizer: δ -aminolevulinic acid (ALA) or its methyl ester (MAL, Metvix® creme). PDT is the method of choice in patients with non-aggressive low risk BCC, for example, the superficial or nodular type not exceeding 2 mm in thickness, when surgery is not possible or is contraindicated. [18]. Usually the cream is applied once per day, five times per week at least 8 to 16 weeks depending on the tumour stage. In a study with 19 patients they evaluated the efficacy of topical immunotherapy for the treatment of BCC and the histological clearance rate was about 90% after 3 months and 84% at 40 months. The 3-year interval of histological clearance rate was 100% for lesions up to 10 mm [62]. Garcia-Martin et al compared the efficacy, cosmetic results and tolerance of Imiquimod and radiotherapy. In the Imiquimod cream group all patients had complete clinical clearance at 24 months of follow-up. In the radiotherapy group patients received treatment 2 or 3

times per week for 5 weeks with a dose of 300 cGy per session (total administered dose was 4,000–7,000 cGy). Aesthetic and functional results were superior in the Imiquimod group, but radiotherapy was better tolerated. [63].

Curettage and electrocoagulation, cryotherapy and laser ablation are methods suitable for small, non-risky basal cell tumours that are not localised on the face and do not have a multifocal character. In the past, chemotherapy was also applied in the treatment of BCC, but unsuccessfully. [64].

With basal cell carcinomas significantly advanced locally, after incomplete excision, in lesions with a high risk of local recurrence or an unacceptable expected cosmetic effect, in elderly patients or with repeatedly recurring lesions, definitive radiotherapy is a suitable solution. [65]. Today there are several types of radiotherapy for BCC: external radiotherapy and also interstitial brachytherapy. About 25% of patients undergo radiation therapy alone for invasive orbital BCC. [66]. Brachytherapy has a theoretical advantage compared to surgery in that it enables the covering of larger areas of the skin with a high dose (macroscopic disease, microscopic disease, safety margin) without the need for irreversible damage to the surrounding tissues. It can be done by means of the interstitial route (the surgical introduction of brachytherapy applicators directly into the tumour tissue by puncture) or superficially. Surface brachytherapy is done by using standard applicators (e.g. Leipzig Applicator, Brock Applicator, Nucletron BV, Netherlands) or custom-made emulsions. Standard applicators are characterised by ease of use and good treatment reproducibility, but they cannot be used for irregular lesions and in a “curved” irregular terrain such as the periocular area. [67].

The side effects after external radiotherapy but also brachytherapy can be dry eye, secondary cataract, ectropion, cicatrization of the lacrimal duct, secondary neovascular glaucoma, radiation retinopathy and maculopathy, radiation optic neuropathy which can lead to blindness.

The recurrence of basal cell carcinoma

Data on the recurrence after surgical treatment of basal cell carcinoma depend on the localization, size, infiltration, histological type, previous treatment options the surgical technique used. The risk of recurrence of BCC after surgery is estimated at 5%–15%. The most recurrences appear on the lower eye lid and in the medial canthus and in infiltrative types. Aggressive histological forms of BCC are associated with a higher risk of recurrence. Lesions with perineural invasion are usually regarded as more aggressive and are associated with higher rates of recurrences. [68].

One of important prognostic factors can be Ki-67, assay of Ki-67 expression is simple and repeatable and is recommended for evaluation of proliferative activity of malignant tumours. In most cases of BCC the values of the Ki-67 index are higher in recurred tumours than in primary BCC. [69, 70].

We can include the apoptotic index as an unexplained prognostic factor of BCC recurrence. In the work of Staibano et al. 60 BCCs were evaluated, 30 of which were BCC1 (non-aggressive type) and 30 BCC2 (aggressive type). BCC1 showed a lower apoptotic index (AI) than BCC2, with the AI of BCC1 from 2.03 – 10.45% (mean value: 5.98%) and the AI of BCC2 from 21.91 – 43.82% (mean value: 39.82%). It is assumed that low AI in BCC1 could indicate a good prognosis. High expression of the Bcl-2 protein is recorded in indolent, slow-growing BCC, while low expression of Bcl-2 occurs in highly aggressive types of BCC [71].

Conclusions

In the scope of onco-ophthalmology, increased attention must be paid to the issue of malignant periocular tumours. Despite a relatively small percentage of invasive diseases today, advanced stages may still occur. Early diagnosis, multidisciplinary cooperation, lifelong dispensary of the patient with early detection of recurrences are all important. Multidisciplinary cooperation and cooperation of the patient in the area of cancer tumours is essential, as it improves the early diagnosis, treatment and survival of patients.

References

1. Prídavková Z, Bieliková A, Ferková N, Lysková D. Recurrent periocular basal cell carcinoma. Case report. *Cesk Slov Oftalmol.* 2021 Spring;77(4):208-213.
2. Saleh GM, Desai P, Collin JRO, Ives A, et al. Incidence of eyelid basal cell carcinoma in England: 2000-2010. *Br J Ophthalmol.* 2017;101(2):209-12.
3. Sun MT, Wu A, Figueira E, et al. Management of periorbital basal cell carcinoma with orbital invasion. *Future Oncol Lond Engl.* 2015 Nov;11(22):3003-10.
4. Furdova A, Kapitanova K, Kollarova A, Sekac J. Periocular basal cell carcinoma - clinical perspectives. *Oncol Rev.* 2020 Apr 30;14(1):420.
5. Madge SN, Khine AA, Thaller VT, Davis G, et al. Globe-sparing surgery for medial canthal Basal cell carcinoma with anterior orbital invasion. *Ophthalmology.* 2010 Nov;117(11):2222-8.
6. Sun MT, Wu A, Huilgol SC, Selva D. Accuracy of Biopsy in Subtyping Periocular Basal Cell Carcinoma. *Ophthal Plast Reconstr Surg.* 2015 Dec;31(6):449-51.
7. Leibovitch I, McNab A, Sullivan T, et al. Orbital invasion by periocular basal cell carcinoma. *Ophthalmology.* 2005 Apr;112(4):717-23.
8. Shields JA, Shields CL, Demirci H, et al. Experience with eyelid-sparing orbital exenteration: the 2000 Tullios O. Coston Lecture. *Ophthal Plast Reconstr Surg.* 2001 Sep;17(5):355-61.
9. Ben Simon GJ, Schwarcz RM, Douglas R, et al. Orbital exenteration: one size does not fit all. *Am J Ophthalmol.* 2005 Jan;139(1):11-7.
10. Furdova A, Lukacko P. Periocular Basal Cell Carcinoma Predictors for Recurrence and Infiltration of the Orbit. *J Craniofac Surg.* 2017 Jan;28(1):e84-7.
11. Wehner MR, Linos E, Parvataneni R, et al. Timing of subsequent new tumors in patients who present with basal cell

- carcinoma or cutaneous squamous cell carcinoma. *JAMA Dermatol.* 2015 Apr;151(4):382–8.
12. Ding S, Sagiv O, Guo Y, et al. Change in Eyelid Carcinoma T Category With Use of the 8th Versus 7th Edition of the American Joint Committee on Cancer: Cancer Staging Manual. *Ophthal Plast Reconstr Surg.* 2019 Feb;35(1):38–41.
 13. Rogers HW, Weinstock MA, Harris AR, et al. Incidence estimate of nonmelanoma skin cancer in the United States, 2006. *Arch Dermatol.* 2010 Mar;146(3):283–7.
 14. Goldenberg G, Karagiannis T, Palmer JB, et al. Incidence and prevalence of basal cell carcinoma (BCC) and locally advanced BCC (LABCC) in a large commercially insured population in the United States: A retrospective cohort study. *J Am Acad Dermatol.* 2016 Nov;75(5):957–966.e2.
 15. Narayanan DL, Saladi RN, Fox JL. Ultraviolet radiation and skin cancer. *Int J Dermatol.* 2010 Sep;49(9):978–86.
 16. Celebi ARC, Kiratli H, Soylemezoglu F. Evaluation of the ‘Hedgehog’ signaling pathways in squamous and basal cell carcinomas of the eyelids and conjunctiva. *Oncol Lett.* 2016 Jul;12(1):467–72.
 17. Yin VT, Merritt H, Esmaeli B. Targeting EGFR and sonic hedgehog pathways for locally advanced eyelid and periocular carcinomas. *World J Clin Cases.* 2014 Sep 16;2(9):432–8.
 18. Poláková K, Murárová Z. Liečba bazocelulárneho karcinómu: Štandardné postupy. MZ SR. Bratislava, 2021.
 19. Hallaji Z, Rahimi H, Mirshams-Shahshahani M. Comparison of risk factors of single Basal cell carcinoma with multiple Basal cell carcinomas. *Indian J Dermatol.* 2011 Jul;56(4):398–402.
 20. Silverman N, Shinder R. What's New in Eyelid Tumors. *Asia Pac J Ophthalmol (Phila).* 2017 Mar-Apr;6(2):143–152.
 21. van Iersel CA, van de Velden HVN, Kusters CDJ, et al. Prognostic factors for a subsequent basal cell carcinoma: implications for follow-up. *Br J Dermatol.* 2005 Nov;153(5):1078–80.
 22. Levi F, Randimbison L, Maspoli M, et al. High incidence of second basal cell skin cancers. *Int J Cancer.* 2006 Sep 15;119(6):1505–7.
 23. Ramachandran S, Fryer AA, Lovatt TJ, et al. Combined effects of gender, skin type and polymorphic genes on clinical phenotype: use of rate of increase in numbers of basal cell carcinomas as a model system. *Cancer Lett.* 2003 Jan 28;189(2):175–81.
 24. Karagas MR, Stukel TA, Greenberg ER, et al. Risk of subsequent basal cell carcinoma and squamous cell carcinoma of the skin among patients with prior skin cancer. *Skin Cancer Prevention Study Group. JAMA.* 1992 Jun 24;267(24):3305–10.
 25. Badri T, Zeglaoui F, Kochbati L, et al. Multiple basal cell carcinomas following radiation therapy for nasopharyngeal cancer. *Presse Medicale Paris Fr* 1983. 2006 Jan;35(1 Pt 1):55–7.
 26. Marcil I, Stern RS. Risk of developing a subsequent nonmelanoma skin cancer in patients with a history of nonmelanoma skin cancer: a critical review of the literature and meta-analysis. *Arch Dermatol.* 2000 Dec;136(12):1524–30.
 27. Chen J, Ruczinski I, Jorgensen TJ, et al. Nonmelanoma skin cancer and risk for subsequent malignancy. *J Natl Cancer Inst.* 2008 Sep 3;100(17):1215–22.
 28. Revenga F, Paricio JF, Vázquez MM, Del Villar V. Risk of subsequent non-melanoma skin cancer in a cohort of patients with primary basal cell carcinoma. *J Eur Acad Dermatol Venereol JEADV.* 2004 Jul;18(4):514–5.
 29. Collins GL, Nickoonahand N, Morgan MB. Changing demographics and pathology of nonmelanoma skin cancer in the last 30 years. *Semin Cutan Med Surg.* 2004 Mar;23(1):80–3.
 30. Lear JT, Smith AG, Strange RC, Fryer AA. Patients with truncal basal cell carcinoma represent a high-risk group. *Arch Dermatol.* 1998 Mar;134(3):373.
 31. Lovatt TJ, Lear JT, Bastrilles J, et al. Associations between ultraviolet radiation, basal cell carcinoma site and histology, host characteristics, and rate of development of further tumors. *J Am Acad Dermatol.* 2005 Mar;52(3 Pt 1):468–73.
 32. Ramachandran S, Fryer AA, Smith A, et al. Cutaneous basal cell carcinomas: distinct host factors are associated with the development of tumors on the trunk and on the head and neck. *Cancer.* 2001 Jul 15;92(2):354–8.
 33. Wallberg P, Kaaman T, Lindberg M. Multiple basal cell carcinoma. A clinical evaluation of risk factors. *Acta Derm Venereol.* 1998 Mar;78(2):127–9.
 34. Wei Q, Matanoski GM, Farmer ER, et al. DNA repair related to multiple skin cancers and drug use. *Cancer Res.* 1994 Jan 15;54(2):437–40.
 35. Hajeer AH, Lear JT, Ollier WE, et al. Preliminary evidence of an association of tumour necrosis factor microsatellites with increased risk of multiple basal cell carcinomas. *Br J Dermatol.* 2000 Mar;142(3):441–5.
 36. Strange RC, El-Genidy N, Ramachandran S, et al. PTCH polymorphism is associated with the rate of increase in basal cell carcinoma numbers during follow-up: preliminary data on the influence of an exon 12-exon 23 haplotype. *Environ Mol Mutagen.* 2004;44(5):469–76.
 37. Ramachandran S, Fryer AA, Smith AG, et al. Basal cell carcinomas: association of allelic variants with a high-risk subgroup of patients with the multiple presentation phenotype. *Pharmacogenetics.* 2001 Apr;11(3):247–54.
 38. Basset-Seguín N, Herms F. Update in the Management of Basal Cell Carcinoma. *Acta Derm Venereol.* 2020 Jun 3;100(11).
 39. Lim LT, Agarwal PK, Young D, et al. The Effect of Socio-Economic Status on Severity of Periocular Basal Cell Carcinoma at Presentation. *Ophthal Plast Reconstr Surg.* 2015 Dec;31(6):456–8.
 40. Furdová A, Horkovičová K, Babál P, et al. Non-melanotic Tumors of the Eyelids Skin and Inner Corner - Basocellular Carcinoma. *Cesk Slov Oftalmol.* 2015 Winter;71(6):293–301.
 41. Ho SF, Brown L, Bamford M, et al. 5 Years review of periocular basal cell carcinoma and proposed follow-up protocol. *Eye.* 2013 Jan;27(1):78–83.
 42. Tzoutzos K, Batistatou A, Kitsos G, et al. Retrospective clinicopathological study of 129 cancerous and 18 precancerous lesions of the eyelids in North-Western Greece. *Int Ophthalmol.* 2017 Feb;37(1):203–8.
 43. Holmes J, von Braunmühl T, Berking C, et al. Optical coherence tomography of basal cell carcinoma: influence of location, subtype, observer variability and image quality on diagnostic performance. *Br J Dermatol.* 2018;178(5):1102–10.
 44. Bălășoiu AT, Mănescu MR, Bălășoiu M, et al. Histological and immunohistochemical study of the eyelid basal cell carcinomas. *Romanian J Morphol Embryol Rev Roum Morphol Embryol.* 2015;56(2 Suppl):803–10.
 45. Zhang L, Huang X, Zhu X, et al. Differential senescence capacities in meibomian gland carcinoma and basal cell carcinoma. *Int J Cancer.* 2016 Mar 15;138(6):1442–52.

46. Quazi SJ, Aslam N, Saleem H et al. Surgical Margin of Excision in Basal Cell Carcinoma: A Systematic Review of Literature. 2020;12(7):e9211.
47. Malhotra R, Huilgol SC, Huynh NT, Selva D. The Australian Mohs database, part I: periocular basal cell carcinoma experience over 7 years. *Ophthalmology*. 2004 Apr;111(4):624–30.
48. Malhotra R, Huilgol SC, Huynh NT, Selva D. The Australian Mohs database, part II: periocular basal cell carcinoma outcome at 5-year follow-up. *Ophthalmology*. 2004 Apr;111(4):631–6.
49. Newlands C, Currie R, Memon A, et al. Non-melanoma skin cancer: United Kingdom National Multidisciplinary Guidelines. *J Laryngol Otol*. 2016 May;130(S2):S125–32.
50. Shi Y, Jia R, Fan X. Ocular basal cell carcinoma: a brief literature review of clinical diagnosis and treatment. *OncoTargets Ther*. 2017 May 8;10:2483–9.
51. Koefman SA, Cooper JS, Beitler JJ, et al. ACR Appropriateness Criteria® Aggressive Nonmelanomatous Skin Cancer of the Head and Neck. *Head Neck*. 2016 Feb;38(2):175–82.
52. Avril MF, Auperin A, Margulis A, Gerbaulet A, Duvillard P, Benhamou E, et al. Basal cell carcinoma of the face: surgery or radiotherapy? Results of a randomized study. *Br J Cancer*. 1997;76(1):100–6.
53. Yu S-S, Zhao Y, Zhao H, Lin J-Y, Tang X. A retrospective study of 2228 cases with eyelid tumors. *Int J Ophthalmol*. 2018 Nov 18;11(11):1835–41.
54. Dirix L, Rutten A. Vismodegib: a promising drug in the treatment of basal cell carcinomas. *Future Oncol Lond Engl*. 2012 Aug;8(8):915–28.
55. Sekulic A, Migden MR, Basset-Seguín N, et al. Long-term safety and efficacy of vismodegib in patients with advanced basal cell carcinoma: final update of the pivotal ERIVANCE BCC study. *BMC Cancer*. 2017 16;17(1):332.
56. Macha MA, Batra SK, Ganti AK. Profile of vismodegib and its potential in the treatment of advanced basal cell carcinoma. *Cancer Manag Res*. 2013;5:197–203.
57. Yin VT, Pfeiffer ML, Esmaeli B. Targeted therapy for orbital and periocular basal cell carcinoma and squamous cell carcinoma. *Ophthal Plast Reconstr Surg*. 2013 Apr;29(2):87–92.
58. Erdem GU, Sendur MAN, Ozdemir NY, et al. A comprehensive review of the role of the hedgehog pathway and vismodegib in the management of basal cell carcinoma. *Curr Med Res Opin*. 2015 Apr;31(4):743–56.
59. Gill HS, Moscato EE, Chang ALS, et al. Vismodegib for periocular and orbital basal cell carcinoma. *JAMA Ophthalmol*. 2013 Dec;131(12):1591–4.
60. Papastefanou VP, René C. Secondary Resistance to Vismodegib After Initial Successful Treatment of Extensive Recurrent Periocular Basal Cell Carcinoma with Orbital Invasion. *Ophthal Plast Reconstr Surg*. 2017 Jun;33(3S Suppl 1):S68–70.
61. Sekulic A, Migden MR, Lewis K et al. ERIVANCE BCC investigators. Pivotal ERIVANCE basal cell carcinoma (BCC) study: 12-month update of efficacy and safety of vismodegib in advanced BCC. *J Am Acad Dermatol*. 2015 Jun;72(6):1021–6.e8.
62. Fahradyan A, Howell AC, Wolfswinkel EM, et al. Updates on the Management of Non-Melanoma Skin Cancer (NMSC). *Healthc Basel Switz*. 2017 Nov 1;5(4).
63. Garcia-Martin E, Gil-Arribas LM, Idoipe M, et al. Comparison of imiquimod 5% cream versus radiotherapy as treatment for eyelid basal cell carcinoma. *Br J Ophthalmol*. 2011 Oct;95(10):1393–6.
64. Coker DD, Elias EG, Viravathana T et al. Chemotherapy for Metastatic Basal Cell Carcinoma. *Arch Dermatol*. 1983; 119(1):44–50.
65. Cisek P, Kieszko D, Bilski M. Interstitial HDR Brachytherapy in the Treatment of Non-Melanocytic Skin Cancers around the Eye. *Cancers*, 13(6),1425.
66. Velter C. Place de la radiothérapie dans le traitement du carcinome basocellulaire. *Ann Dermatol Vénéréologie*. 2018 Nov 1;145:VS30–5.
67. Leibowitch I, McNab A, Sullivan T, et al. Orbital Invasion by Periocular Basal Cell Carcinoma. *Ophthalmology*, 2005; 112: 717–723.
68. Honavar SG, Manjandavida FP. Tumors of the ocular surface: A review. *Indian J Ophthalmol*. 2015 Mar;63(3):187–203.
69. Süngü N, Kiran MM, Tatli Doğan H, et al. Evaluation of p53 and Ki67 Expression Profiles in Basal Cell Carcinomas in a Usual and an Unusual Location. *Turk Patoloji Derg*. 2018;34(2):165–70.
70. Kramer E, Herman O, Frand J, et al. Ki67 as a biologic marker of basal cell carcinoma: a retrospective study. *Isr Med Assoc J IMAJ*. 2014 Apr;16(4):229–32.
71. Staibao S, Lo Muzio L, Pannone G. Interaction between bcl-2 and P53 in neoplastic progression of basal cell carcinoma of the head and neck. *Anticancer Res*. 2001 Nov-Dec;21(6A):3757–64.

Disclosures

Received 09.01.2023

Accepted 16.01.2023

Corresponding author: Zuzana Pridavková – zuzana.pridavkova@gmail.com.

Authors' contributions: Z. Pridavková: Conceptualization, Project administration, Investigation, Writing-original draft; A. Furdová: Conceptualization, Project administration, Writing-review & editing; K. Benca Kapitánová: Editing, Investigation; R. Vida: editing; P. Žiak: editing; I. Popov: editing.

Disclaimer: The opinions presented in this article are those of the authors and do not necessarily represent those of their institutions.

Financial support: no financial support received.

Conflict of interest statement: None of the authors has conflict of interest with this submission.

Financial/proprietary interest: None of the authors has financial interest related to this study to disclose.

Declaration of Helsinki: The manuscript does not report the results of an experimental investigation on human subjects.

Informed Consent: This article does not include results of experimental investigations on human subjects.

Abbreviations: BCC – Basal cell carcinoma; SCC – Squamous cell carcinoma; NMSC – Non-melanoma skin cancer; NCR – National Cancer Registry; GLI – Glioma-Associated Oncogene; FDA – Food and Drug Administration; EMA – European Medicines Agency.