

<https://doi.org/10.31288/oftalmolzh202424951>

Pediatric dog-bite injuries of the ocular adnexa

N.F. Bobrova, S.A. Tronina

SI "The Filatov Institute of Eye Diseases and Tissue Therapy of the NAMS of Ukraine";

Odesa (Ukraine)

Background: Although domestic dogs have been human companions for thousands of years, their uncontrolled aggressive behavior may cause a canine attack on a human, leading to severe injuries. As much as 1.5% of the population receives a dog bite requiring medical attention annually and dog bite prevalence is twice as high among children when compared to the population of other age groups.

Purpose: To review the clinical features of and outcomes of surgical treatment for pediatric dog-bite injuries to the ocular adnexa.

Material and Methods: We retrospectively reviewed the clinical features of and outcomes of surgical treatment for pediatric dog-bite injuries to the ocular adnexa in 25 children aged 2-13 years (mean age, 5.5 ± 3.1 years).

Results: Bites affecting the lower eyelid were most common (68%). An injury to the lacrimal duct in the form of canalicular avulsion was seen in 52% of all cases and 76.9% of children with a lower eyelid injury. All children received urgent primary surgical wound repair (PSWR) with suture wound closure. When a laceration of the inferior canaliculus occurred, canaliculus repair and intubation was performed using different methods.

Conclusion: During PSWR, necrosed tissue should be removed with preservation of vital tissue as much as possible, because adequate vascularization and young age contribute to active tissue reparation. Restoration of the integrity of and passage through the lacrimal duct are essential to prevent postoperative epiphora.

Keywords:

bite injury, ocular adnexa, children

Introduction. Dog companionship and interaction may contribute to human health and well-being and child development and education. Dogs are not only pets but they may also perform various social actions e.g. to benefit patients in hospitals and rehabilitation centers. However, a dog's uncontrolled aggressive behavior may cause a canine attack on a human, leading to severe injuries. As much as 1.5% of the population receives a dog bite requiring medical attention annually and dog bite prevalence is twice as high among children when compared to the population of other age groups [1-3]. Child initiated interactions, such as approaching the dog while eating or surprising it while sleeping, seem to trigger up to 86% of bite accidents at home [4]. The incidence of dog bite injuries in developed nations tends to increase [5-7]. Thus, in the UK, the number of yearly hospital admissions for dog bites increased by 76% from 2005 to 2015 [8].

The patients most likely to suffer dog bite injuries are children, and these injuries have been previously reported to account for 3-4% of pediatric emergency visits, up to 40% of all pediatric traumas [3, 9]. The majority of bite accidents (about 75%) occur in the home environment and most pediatric victims have been reported to be bitten by a familiar dog [1].

The purpose of the study was to review the clinical features of and outcomes of surgical treatment for pediatric dog bite injuries to the ocular adnexa.

Material and Methods

Twenty-five children (age range, 2 to 13 years; mean age plus or minus standard deviation, 5.5 ± 3.1 years) with dog bite injuries to the ocular adnexa were treated at the Department of Pediatric Eye Pathology, the Filatov Institute of Eye Disease and Tissue Therapy. Of these, 16 (64%) were boys and 9 (36%) were girls, and 88% were bitten by their dog.

This study included human participants, was approved by the local bioethics committee and adhered to the tenets of the Declaration of Helsinki. Informed consent was not obtained due to the retrospective nature of the study. This study did not include animal experiments.

Statistical analyses were conducted using spreadsheets and Statistica 8.0 (StatSoft, Tulsa, OK, USA) software. Nominal data are presented as number and percentage. The normal distribution of quantitative data was tested using the Shapiro–Wilk W-test. Mean (M) and standard error of mean (m) values were calculated for normally distributed age data.

Results

An isolated lower eyelid laceration was most common (68%) (Fig. 1A), followed by a laceration of both eyelids (24%) (Fig. 1B), and an isolated upper eyelid laceration (8%) (Fig. 1C). An injury to the lacrimal duct in the form of canalicular avulsion was seen in 52% of all cases and 76.9% of children with a lower eyelid injury. An eyelid laceration was accompanied by other facial injuries in 33.3% of children, and was characterized by a loss of tissue mass

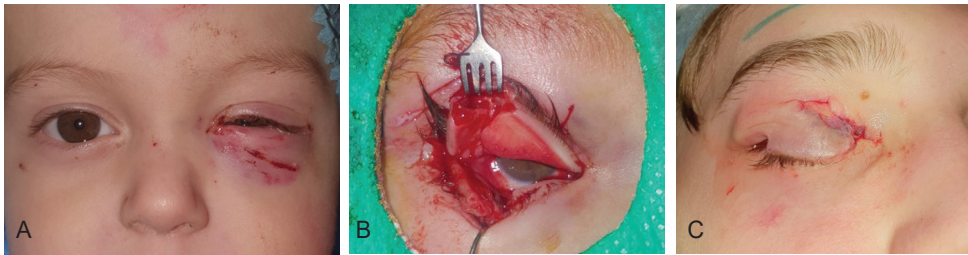


Fig. 1. Location of dog-bite injuries to the ocular adnexa: (A) lower eyelid laceration with an avulsion of the inferior lacrimal canaliculus, (B) laceration of both eyelids with partial avulsion of the upper eyelid, and (C) isolated upper eyelid laceration and avulsion

in 27.8%. Corneal and conjunctival erosion was seen in 16% of children.

All children received urgent primary surgical wound treatment (PSWR) with suture wound closure. Bite wounds were thoroughly cleansed of any dog's saliva, food debris and other biological contaminants which could cause infection, hamper healing and contribute to increased inflammation. For this purpose they were copiously irrigated with antiseptic (hydrogen peroxide 3% and povidone-iodine 10%). Accurate apposition of the wound margins, sparing of damaged tissue and avoidance of aggressive necrosectomy was important to achieve good cosmesis. During PSWR, a surgical microscope was used to assess the vitality of damaged tissues by signs of preserved circulation (a pink skin color and the presence of functioning capillary vessels in the muscle tissue). Obviously necrotic tissues (i.e., those of a dark blue or black color) were debrided. The presence of apparent mechanical tissue damage along the wound margin was not an indication for radical excision of these areas, which corresponded to the principle of spared debridement that we adhere to.

When a laceration of the inferior canaliculus was found during PSWR, canaliculus repair and intubation was performed using a polyvinyl chloride cannula (a 24-G venous catheter; Fig. 2A-B) or, less commonly, a metal cannula for the anterior chamber. For this purpose, a conical probe was passed through the lacrimal punctum to the non-damaged distal canalicular portion and, after the aperture in the proximal portion of the canaliculus was identified, the probe was passed through to the lacrimal sac. Thereafter, the conical probe was replaced by the intubation cannula which was placed along the entire length of the inferior canaliculus from the lacrimal punctum to the lacrimal sac. A plastic cannula was helpful to avoid pain in a small child; it, nevertheless, had to be secured to the eyelid skin for reliable fixation and prevention of its early removal by the child. The presence of support within the canalicular lumen facilitated accurate apposition of the wound margins before suturing. An interrupted 6-0 silk suture was placed in the

gray line to perfectly align the lamellae of the eyelid and restore the contour of the inferior eyelid margin.

Discussion

In this study, like in the studies by other researchers [10-12], most dog-bite child victims were of pre-school-age, the age at which children actively familiarize themselves with the surrounding world, but have not enough knowledge about the potential danger of animals (including own pets), and are not always adequately controlled by adults. Bites affecting the head/neck region are most common in pre-school-age dog-bite child victims. This is not only due to a low height of these children, but primarily due to their behavior (child-initiated interactions such as approaching the dog while eating or surprising it while sleeping or playing) [13-16]. Others [3, 9] reported that the pediatric patients who were bitten by dogs in the head or neck were more likely to be children under the age of ten, with an equal to slight disposition towards girls than boys. However, in the current study, the number of boys was almost twice as large as the number of girls.

It has been reported [3,17] that 61.7-75.5 % of patients sustaining head and neck dog bites requires surgical intervention in the operating room for proper wound repair. Given the location of facial dog bite injuries (especially injuries to the middle third of the face, which, even if small, may result in serious problems with cosmesis and functional abnormalities), high-quality PSWR is of special importance. The final treatment outcome and the requirement for reconstructive plastic surgery depend to a considerable extent on adequate restoration of the anatomy of the ocular adnexa. In addition, many researchers [1, 3, 18] note that PSWR in such cases requires specialized surgical skills.

In the current study, lower eyelid laceration was noted in the majority of cases, which can be explained the anatomical predisposition of the lower eyelid (especially the medial third of the eyelid, the region of the strongest adhesion) for laceration from dog bites. Obviously, an injury to the medial aspect of the lower eyelid resulted in an avulsion

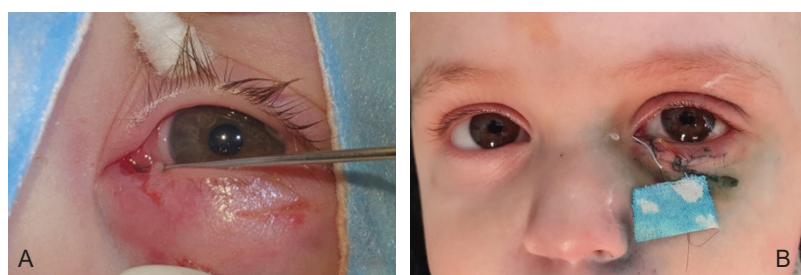


Fig. 2. Surgical treatment of a dog-bite injury to the lower eyelid with an involvement of the inferior lacrimal canaliculus. (A) Intraoperative photograph of revision of the site of avulsion of the inferior lacrimal canaliculus with identification of the proximal portion using a conical probe. (B) State of the patient on day 4 after primary surgical wound treatment. Note the lacrimal canaliculus intubated with a polyvinyl chloride cannula.

of the inferior canaliculus. Given its special role in lacrimal drainage, and to prevent postoperative epiphora, it was critically important to repair the canaliculus during PSWR. Interestingly, an eyelid wound was commonly inflicted by the canine maxillary teeth and, in accordance with the maxillary jaw size and the extent of jaw opening, the wounds inflicted by the mandibular teeth were noted on the child's ipsilateral cheek or beneath his/her lower jaw.

Until recently, there has been no agreement in the literature regarding one preferred strategy of surgical wound treatment (i.e., whether it is reasonable to use primary or secondary wound closure for bite wounds). Recent studies, however, have demonstrated the advantages of primary wound closure (most commonly, direct wound suturing), which enables more delicate scarring, lower probability for secondary infection, and no need for care for open wounds [3, 10, 12, 19]. Direct primary bite-wound closure with copious wound irrigation with antiseptics and broad-spectrum antibiotics (effective against Gram-positive and Gram-negative pathogens) was used in all patients of the current study, and there were no postoperative infectious complications in any patients. Necrosed tissue was removed with preservation of vital tissue as much as possible to prevent the development of significant skin and soft-tissue defects and enable adequate blood supply to facial tissues for smooth healing. The feasibility of this approach was confirmed by the healing of residual mild colobomas of the eyelid tarsal margin with a trend for occurrence of defect filling.

Conclusion

Pediatric dog-bite injuries of the ocular adnexa more commonly occurred in active boys, with the most common injury location being the medial aspect of the lower eyelid, with a frequent lacrimal canaliculus involvement. During PSWT, necrosed tissue should be removed with preservation of vital tissue as much as possible, because adequate vascularization and young age contribute to active tissue reparation. Restoration of the integrity of and passage through the lacrimal duct are essential to prevent postoperative epiphora.

References

- Ozanne-Smith J, Ashby K, Stathakis VZ. Dog bite and injury prevention: analysis, critical review, and research agenda. *Inj Prev*. 2001;7(4):321–6.
- Gilchrist J, Sacks JJ, White D, et al. Dog bites: still a problem? *Inj Prev*. 2008;14(5):296–301.
- Lee ChJ, Tiourin E, Schuljak S, Phan J, et al. Surgical Treatment of Pediatric Dog-bite Wounds: A 5-year Retrospective Review. *West J Emerg Med*. 2021 Nov; 22(6): 1301–1310. doi: 10.5811/westjem.2021.9.52235
- Meints K, Brelsford V, De Keuster T. Teaching Children and Parents to Understand Dog Signaling. *Vet Sci*. 2018; 5: 257. doi: 10.3389/fvets.2018.00257
- Chen HH, Neumeier AT, Davies BW, et al. Analysis of pediatric facial dog bites. *Craniofacial Trauma Reconstr*. 2013;6(4):225–31.
- Cook JA, Sator SE, Soleimani T, et al. An epidemiological analysis of pediatric dog bite injuries over a decade. *J Surg Res*. 2020;246:231–5.
- McLoughlin RJ, et al. Hospitalizations for pediatric dog bite injuries in the United States. *J Pediatr Surg*. 2020;55(7):1228–33. doi: 10.1016/j.jpedsurg.2019.06.025.
- HSCIC (Health and Social Care Information Centre) Accident and Emergency Attendances in England – 2014–15. (2015). Available online at: <https://digital.nhs.uk/data-and-information/publications/statistical/hospital-episode-statistics-for-admitted-patient-care-outpatient-and-emergency-and-emergency-data/provisional-monthly-hospital-episode-statistics-for-admitted-patient-care-outpatients-and-emergency-data-april-2014-to-february-2015>
- O'Brien DC, Andre TB, Robinson AD, Squires LD. Dog bites of the head and neck: an evaluation of a common pediatric trauma and associated treatment. *Am J Otolaryngol*. 2015 Jan-Feb; 36(1): 32–38. doi: 10.1016/j.amjoto.2014.09.001.
- Wu PS, Beres A, Tashjian DB, Moriarty KP. Primary repair of facial dog bite injuries in children. *Pediatric emergency care*. 2011;27(9):801–3. doi: 10.1097/PEC.0b013e31822c1112.
- Eppley BL, Schleich AR. Facial dog bite injuries in children: treatment and outcome assessment. *The Journal of craniofacial surgery*. 2013;24(2):384–6. doi: 10.1097/SCS.0b013e31827fee33.
- Rui-feng C, Li-song H, Ji-bo Z, Li-qi W. Emergency treatment on facial laceration of dog bite wounds with immediate primary closure: a prospective randomized trial study. *BMC emergency medicine*. 2013;13 (Suppl 1): S2. doi: 10.1186/1471-227x-13-s1-s2.
- Touré G, Angoulangouli G, Méningaud JP. Epidemiology and classification of dog bite injuries to the face: a prospective study of 108 patients. *J Plast Reconstr Aesthet Surg*. 2015;68:654–658. doi:10.1016/j.bjps.2015.01.001
- Mannion CJ, Graham A, Shepherd K, Greenberg D. Dog bites and maxillofacial surgery: what can we do? *Br J Oral Maxillofac Surg*. 2015;53:522–525. doi: 10.1016/j.bjoms.2015.02.022.
- Macedo JL, Rosa SC, Queiroz MN, Gomes TG. Reconstruction of face and scalp after dog bites in children. *Rev Col Bras Cir*. 2016;43:452–457. doi: 10.1590/0100-69912016006007.
- Kumar R, Deleviannis FW, et al. Neurosurgical sequelae of domestic dog attacks in children. *J Neurosurg Pediatr*. 2017;19:24–31. doi: 10.3171/2016.7.PEDS1646.
- Chen T, Karim M, Grace ZT, Magdich AR, Carniol Eric C, et al. Surgical management of facial dog bite trauma: A contemporary perspective and review. *World J Otorhinolaryngol Head Neck Surg*. 2023 Jun; 9(2): 123–130.
- Ambro BT, Wright RJ, Heffelfinger RN. Management of bite wounds in the head and neck. *Facial Plast Surg*. 2010;26(6):456–63. doi: 10.1055/s-0030-1267720.
- Foster MD, Hudson JW. Contemporary update on the treatment of dog bite: injuries to the oral and maxillofacial region. *J Oral Maxillofac Surg*. 2015;73:935–942.

Disclosures

Received 17.09.2023

Accepted 08.11.2023

Author Contributions. NFB: Conceptualization, Writing – review & editing; SAT: Writing – original draft, Formal Analysis, Writing – review & editing. All authors read and approved the final manuscript.

Financial support: no financial support received.

Conflict of interest statement: None.

Financial/proprietary interest: None.