

<https://doi.org/10.31288/oftalmolzh202513033>

## Pterygium Excision with Conjunctival Autograft without Suture and Glue in Rural India

Ramya M. <sup>1</sup>, Mahesh J.B. <sup>1</sup>, Varun Raju  <sup>2</sup>

<sup>1</sup> Chikkbhallapur Institute of Medical Sciences  
Chikkbhallapur (India)

<sup>2</sup> Akash Institute of Medical Sciences  
Bengaluru (India)

**Purpose:** To determine the rate of complications and surgical outcome of using the sutureless, glueless technique for conjunctival autograft placement in cases of primary pterygium.

**Materials and Methods:** A prospective interventional study was conducted in 40 eyes of 40 patients with primary nasal pterygium with grades 2-4 who presented to the ophthalmology Outpatient Department at Chikkbhallapur Institute of Medical Sciences at Chikkbhallapur were enrolled for the study. The patients who needed surgical excision were considered for the study after obtaining informed consent as per the declaration of Helsinki. Visual Acuity was recorded using Snellen's chart. Demographic data, clinical presentations, management, and complications were noted. Data were analysed using Excel Data Analysis Tool and Jamovi 2.3.20 statistical analysis tool.

**Results:** A total of 40 patients were included in the study. The mean age group was 48.1 years (the minimum being 28 and the maximum being 70, and pterygium generally prevailed in the age group between 30 and 60 years. Gender selection was not conducted in this study. However, random enrollment indicated that the F:M ratio was 4:1. The recurrence rate was very low, 5% in cases using the glueless, sutureless technique, and the other complications were comparable with other techniques: graft displacement 7.5%, graft missing on the first post operative day in 2.5%, graft wrinkling and shrinkage in 10%, postoperative foreign body sensation and pain in 30%, and photophobia in 15%.

**Conclusion:** This technique proved that the recurrence rate was very low, which is the main aim of pterygium excision. The BCVA was significantly improved after the operation.

### Keywords:

pterygium excision, sutureless technique, glueless technique, conjunctival autograft

### Introduction

Pterygium, a word derived from “pterygium” (ancient Greek for wing), is a wing-shaped, fibrovascular overgrowth arising from subconjunctival tissue extending across the limbus onto the cornea. [1] It is a degenerative condition of the subconjunctival tissue which proliferates as vascularized granulation tissue to invade the cornea, destroying superficial layers of stroma and Bowman's membrane, the whole being covered by conjunctival epithelium. [2] The prevalence rate of primary pterygium varies from 0.7% to 31% in various populations around the world. [3] Surgery is the only effective treatment for pterygium, though recurrences are common. With simple excision techniques (that is, excising the pterygium and leaving bare sclera), the risk of recurrence has been reported to be upwards of 80%. Pterygium excision combined with a tissue graft has a lower risk of recurrence. In conjunctival autograft surgery, conjunctival tissue from another part of the person's eye along with limbal tissue is resected in one piece and used to cover the area from which the pterygium was excised. Another type of tissue graft surgery for pterygium is amniotic membrane graft, whereby a

piece of donor amniotic membrane is fixed to the remaining limbus and bare sclera area after the pterygium has been excised [4]. Other common methods of conjunctival autograft placement are with the help of sutures or the use of fibrin glue.

After pterygium surgery, the conjunctival autograft is secured in place with either absorbable or nonabsorbable sutures. The presence of sutures is associated with various complications, i.e. discomfort, increased lacrimation, and at times suture-related granuloma or abscess. With the invention of newer alternatives such as fibrin glue and autologous blood, suture-related complications have come to a halt.

### Materials and Methods

A prospective interventional study in 40 eyes of 40 individuals with primary nasal pterygium with grades 2-4 were considered for the study who needed surgical excision and they were enrolled in the study at Government Hospital, Chikkbhallapur, Karnataka, India, after obtain-

ing informed consent as per the declaration of Helsinki. Best-corrected visual acuity (BCVA) was recorded using Snellen's chart. Intra-ocular pressure (IOP) was measured using ApplanationGoldmann's tonometer. Slit-lamp examination of an anterior segment and fundus examination was done using Indirect Ophthalmoscopy. Data were entered into MS Excel sheet, data were analysed using Excel Data Analysis Tool and Jamovi 2.3.20 statistical analysis tool.

#### *Inclusion criteria*

All the patients who presented to the Outpatient Department at Chikballapur Institute of Medical Sciences in the age group of 20-70 years with Primary Pterygium (Grades 2-4) were included in the study.

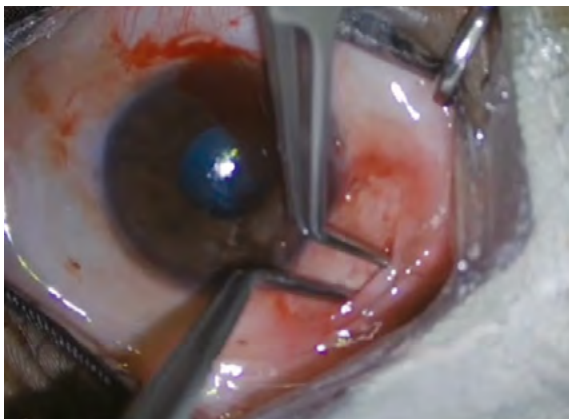#### *Exclusion criteria*

Recurrent Pterygium, Grade 1 or Trace Pterygium, Temporal Pterygium, Glaucoma, and History of Previous Ocular Surgery or Trauma were excluded from the study. Patients with pre-existing glaucoma, those with a history of previous ocular surgery within the last 6 months, and those with lid and ocular surface disorders like blepharitis, dry eyes, symblepharon, double head pterygium, previous trauma, and active infections were excluded.

Pterygium was graded depending on the extent of corneal involvement: Grade I – crossing the limbus, Grade II – mid-way between the limbus and pupil, Grade III – reaching up to the pupillary margin; and Grade IV – crossing pupillary margin. In total, 40 patients were operated upon, of which 15 patients had Grade I pterygium, 15 had Grade III pterygium, and 10 had Grade IV pterygium. Surgeries were performed by a set of two very experienced surgeons who have vast exposure in surgical management of pterygium. Both of them used similar technique in all cases to avoid any surgical bias regarding recurrence.

#### *Surgical technique*

Peribulbar anesthesia with 2% lignocaine was given preoperatively. The body of the pterygium was dissected 4 mm from the limbus, down to the bare sclera. Pterygium was removed from the cornea by avulsion. Only the thickened portion of the conjunctiva and the immediately adjacent and subjacent Tenon's capsule were excised. Large



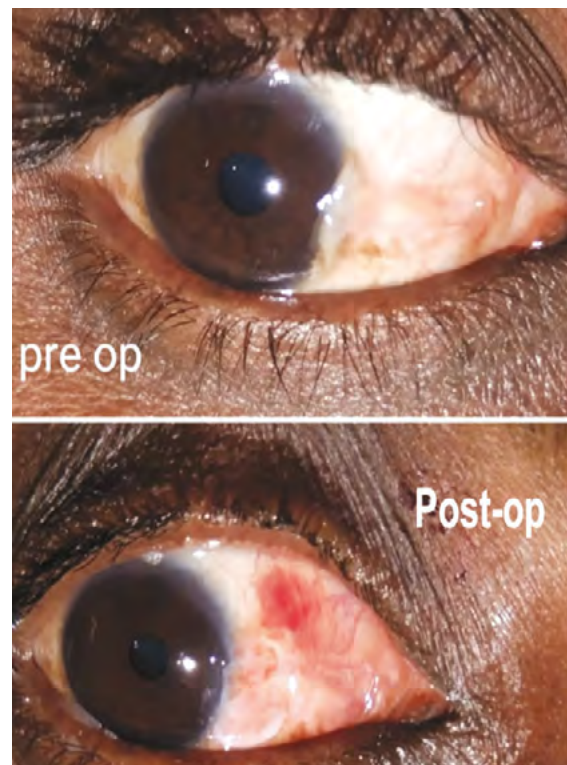
**Figure 1.** Ironing of graft

hemorrhages were tamponade with direct compression. Oversized graft by 1 mm was removed after measuring with the Castroviejo-caliper. The graft was taken from the superior-temporal position.

The graft was resected using conjunctival scissors. No fluid or air was used for making the graft. Care was taken to include as little as possible of Tenon's tissue in the graft. The graft was placed on the bare sclera and positioned to maintain the limbus-limbus orientation. The graft was kept as opposed to the scleral bed by ironing the graft using two McPherson angled lenses holding forceps (Figure 1). During small bleeds in the scleral bed, there is always a small ooze of the serum which acts as an adhesive. The eye was carefully patched with pressure for 24 hours. First post operative day image as shown in Figure 2, which shows pre-operative and post-operative image of pterygium. The Postoperative treatments were: Moxifloxacin and dexamethasone combination eye drops in tapering dose over one month period starting from 6 drops a day for a week, 4 drops a day for 2nd week, 2 drops a day for the 3rd week, 1 drop a day for the 4th week. Sodium hyaluronate 0.1% eye drops 4 times a day for 1 month. The follow-up period was 3 months.

#### **Results**

A total of 40 patients were taken for the study. The mean age group was  $48.1 \pm 12.14$  years, with the minimum being 28 and the maximum being 70 (Table 1). The median was 47 years and the mode was 36 years. The pterygium generally prevails in the age group between 30 to



**Figure 2:** Pre-operative and post-operative images of pterygium excised eyes.

**Table 1.** Descriptive statistics of patient age

Particulars	Years
Mean	48.10
Standard Error	1.92
Median	47.00
Mode	36.00
Standard Deviation	12.14
Minimum	28.00
Maximum	70.00

60. The Frequency of the ages of the patients in the present study is presented in Table 2.

Gender selection was not done in the present study. However, random enrollment indicated that the number of females and males was 32 (80%) and 8 (20%), respectively (Table 3). F: M ratio was 4:1.

Of the 40 patients, 20 had left eye nasal pterygium and 20 had right eye nasal pterygium. At the time of enrollment, 15 patients had the pterygium Grade II, 15 patients had the pterygium Grade III, and 10 patients had the pterygium Grade IV.

Regarding post-operative complications, the recurrence rate was very low (5% in the case of the glueless, sutureless technique). Other complications were graft displacement in 7.5%, graft missing on POD-1 in 2.5%, graft wrinkling and shrinkage in 10%, photophobia in 15%, postoperative foreign body sensation, and pain in 30%. Table 4 also shows the comparative outcome of the complications among patients who had different grades of pterygium while enrolling for the operation. However, there was no significant effect on the outcome of complications (P=0.0515) (Table 4).

Comparison of Best Corrected Visual Acuity (BCVA) indicated that the BCVA was highly significantly improved in this method after 3 months of operation (P<0.001) (Table 5).

**Table 2.** Age range and frequency

Age range	Frequency (n)	Percentage (%)
20-30	2	5.00
31-40	11	27.50
41-50	10	25.00
51-60	11	27.50
61-70	6	15.00
Total	40	100.00

**Table 3.** Gender distribution

Gender	Number	Percentage
Male	8	20.00
Female	32	80.00
Total	40	100

**Table 5.** BCVA of the patients before and after 3 months of operation

BCVA	Pre-op N	3m Post-op N	X <sup>2</sup>
6/6	0	3	P<0.001
6/9	3	14	HS
6/12	14	0	
6/24	10	23	
6/36	13	0	
Total	40	40	

BCVA – Best Corrected Visual Acuity

**Discussion**

Conjunctival sutures used in pterygium surgery are not only time-consuming process but also may lead to local complications such as discomfort, scarring, granuloma, or infection. Plasma-derived products such as fibrin glue may

**Table 4.** Number of Post-operative complications versus the grades of pterygium at the time of operation (Percentage in brackets)

Complications	Grade-2	Grade-3	Grade-4	Total	P value
Nil	7 (17.5)	4 (10.0)	1 (2.5)	12 (30)	0.0516
Graft displacement	1 (2.5)	1 (2.5)	1 (2.5)	3 (7.5)	NS
Graft missing on POD 1	0	1 (2.5)	0	1 (2.5)	
Graft wrinkling and shrinkage	2 (5.0)	1 (2.5)	1 (2.5)	4 (10)	
Photophobia	1 (2.5)	3 (7.5)	2(5.0)	6 (15)	
Postoperative foreign body sensation and pain	4 (10.0)	5 (12.5)	3 (7.5)	12 (30)	
Recurrence	0	0	2 (5.0)	2 (5.0)	
Sub-total of Post Op complications	8 (20)	11(27.5)	9 22.5)	28 (70)	
Total	15 (37.5)	15 (37.5)	10 (25)	40 (100)	

POD-1 – Post operative day 1

produce possible hypersensitivity reactions whereas the risk of viral transmission remains theoretically possible. We describe a simple method of achieving conjunctival autograft adherence during pterygium surgery avoiding potential complications associated with the use of fibrin glue or sutures.

Although autologous limbalconjunctival grafting is an effective method for the prevention of recurrence after pterygium surgery, suturing of the autograft is difficult and necessitates surgical experience and technical skill [4].

The mean age in our study was  $48.1 \pm 12.14$  years. In a study conducted by Bhatia et al the mean age was 47.7 years, which corresponds to the present study. In our study, the minimum age was 28 years and the maximum was 70 years. In the study of Bhatia et al the minimum age was 28 years and the maximum was 70 years which was similar to our study [5].

Bhaskar et al. found that the female:male ratio was 3:1, and in our study the F: M ratio was 4:1, similar to their study. [6]

In a study conducted by Sharma et al, graft-related complications were found: graft edema in seven (15.55%) and graft retraction two (4.44%). In our study we found that graft displacement (7.5%), graft wrinkling, graft retraction (10%) were the graft related complications [7]. Koranyi et al found that the total recurrence rate in their study was 14%, whereas in our study it was found to be 5% [8]. Ti et showed that postoperative inflammation increases the risk of pterygium recurrence [9]. Suzuki et al reported that silk or nylon sutures may cause conjunctival inflammation and Langerhans cell migration into the cornea [10].

The rate of recurrence was 5% in this study, which can most probably be attributed to the rural group of patients and their respective professions and also the study population, which was comparatively less.

One of the main advantages of this method in a rural setting is the cost factor, as there is no use of fibrin glue and sutures. So, the material cost of the surgery decreases significantly, making it accessible to a wider population in rural areas.

The other key advantages are as follows:

1. The time taken to put sutures to the conjunctival autograft is far more compared to the above mentioned method and also more tedious for the surgeon.

2. The post operative irritation and pricking sensation in patients in whom the autograft has been sutured, is far greater as compared to the above mentioned technique.

### Conclusion

Pterygium excision with conjunctival autograft without suture and glueless technique is the most cost-effective method, which is of great importance; especially in a rural setup as the fibrin glue is expensive and the patients are not affordable. It is also less time consuming than autograft fixation using sutures. The recurrence rate is very low, which is the main aim of pterygium excision. Other complications are comparable to those of other techniques.

### References

1. Sihota R, Tondon R, editors. Parson's Diseases of Eye. 19th ed. India: Butterworth-Heinemann; 2003. Diseases of conjunctiva; p. 193.p. 4.
2. Duke-Elder SS. System of Ophthalmology. Vol. VIII. London: Henry Kimpton; 1965. 574 p.
3. Detels R, Dhir SP. Pterygium: a geographical study. Archives of Ophthalmology. 1967;78(4):485-91
4. Clearfield E, Muthappan V, Wang X, Kuo IC. Conjunctival autograft for pterygium. Cochrane Database of Systematic Reviews. 2016 Feb 11;2(2):CD011349.
5. Bhatia J, Varghese M, Narayanadas B, Bhatia A. Cut-and-place technique of pterygium excision with autograft without using sutures or glue: Our experience. Oman journal of ophthalmology. 2017;10(2):81-6.
6. Bhaskar G, Ambastha A, Sinha BP, Ali MS, Kumar P, Sinha R. Pterygium Surgery with Conjunctival Autograft (CAG)-No Glue, No Stitch Technique. Journal of Indira Gandhi Institute Of Medical Science. 2019;5(2):155-7.
7. Sharma V, Tinna A, Singh A, Singh AK, Ambiya V. Sutureless and glue-free limbal-conjunctival autograft in primary and recurrent pterygium: A pilot study. Indian Journal of Ophthalmology. 2022;70(3):783-7.
8. Koranyi G, Seregard S, Kopp ED. Cut and paste: a no suture, small incision approach to pterygium surgery. British journal of ophthalmology. 2004;88(7):911-4.
9. Ti SE, Chee SP, Dear KB, Tan DT. Analysis of variation in success rates in conjunctival autografting for primary and recurrent pterygium. British journal of ophthalmology. 2000;84(4):385-9.
10. Suzuki T, Sano Y, Kinoshita S. Conjunctival inflammation induces Langerhans cell migration into the cornea. Current eye research. 2000 ;21(1):550-3.

### Disclosures

Received: 12.06.2024

Accepted: 08.10.2024

### Information about authors and disclosure of information

**Corresponding author:** Ramya.M. – ramya8366@gmail.com

**Author's contribution.** Ramya M. – conceptualisation, data collection, data analysis, manuscript preparation and review; Mahesh J.B. – conceptualisation, data collection, data analysis, manuscript preparation and review; Varun Raju – conceptualisation, data collection, data analysis, manuscript preparation and review. All authors analysed the results and approved the final version of the manuscript to publication.

**Financial support.** No.

**Conflict of interest statement.** None of the following authors have any proprietary interests or conflicts of interest related to this submission. This submission has not been published anywhere previously and that it is not simultaneously being considered for any other publication.

**Disclaimer.** The views expressed in this article are based on our research and do not necessarily represent the official position of our institution or funder.