

<https://doi.org/10.31288/oftalmolzh202415460>

Retinal changes as evidenced by fundoscopy and their frequencies in patients with COVID-19 with different variants of the angiotensin-converting enzyme gene

K. M. Hutsaliuk^{1,2,3}, Z. I. Rossokha⁴, N. Iu. Skalska¹, N. A. Ulianova³

¹ Volyn Regional Clinical Hospital

² Lesya Ukrainka Volyn National University
Lutsk (Ukraine)

³ SI "The Filatov Institute of Eye Diseases and Tissue Therapy of the NAMS of Ukraine"
Odesa (Ukraine)

⁴ SI "Reference-centre for molecular diagnostic of Public Health Ministry of Ukraine"
Kyiv (Ukraine)

Purpose: To evaluate the relationship between angiotensin-converting enzyme (ACE; rs4340) gene variants and the retinal changes as evidenced by fundoscopy in patients with various clinical courses of COVID-19.

Material and Methods: Ninety-four COVID-19-positive patients (188 eyes) were included in the study. They had an extremely severe course, severe course, or moderately severe course of the disease with decompensated or compensated comorbidity. We evaluated the distribution of ACE gene genotypes among patients and determined the retinal changes in COVID-19 patients with different ACE genotypes. Fundus images were obtained with a handheld fundus camera to identify clinically significant and insignificant retinal changes. A molecular and genetic study of ACE gene (rs4340) variants was carried out using allele-specific polymerase chain reaction (PCR). Statistical analysis of correlations between the course of COVID-19 and the presence of retinal changes as well as between the ACE gene variant and the presence of retinal changes was conducted.

Results: Among the analyzed individuals, 28 (29.6%), 47 (50.5%) and 19 (19.9%) were found to have the II genotype, ID genotype, and DD genotype, respectively. We found no significant correlation between metabolic status, severity of COVID-19 course and the ACE gene variant. No significant difference was found among groups of COVID-19 patients of different ACE genotypes with respect to the distribution of particular retinal changes. There was an increase ($p < 0.001$) in the risk of clinically significant retinal changes in patients with the DD genotype compared to patients with the II genotype and those with the ID genotype ($p < 0.05$).

Conclusion: The risk of clinically significant retinal changes is higher in COVID-19 patients with ACE genotype DD than in those with genotype II or ID ($p < 0.001$).

Ключові слова:

retina, fundoscopy, retinal changes, COVID-19, angiotensin converting enzyme (ACE) gene variants

Introduction

Recently, increasing attention has been drawn to the relationships between gene polymorphisms and the course of a disease (e.g. COVID-19). Kim and Jeong [1] evaluated the correlation between the case fatality rate of COVID-19 and the genetic polymorphisms of several genes, e.g., interferon-induced transmembrane protein 3 (IFITM3). Aladawy and colleagues [2] investigated the role of a polymorphism in the promoter region of IL6 gene as a predictor of disease severity in COVID-19 patients. It has been concluded that gene polymorphism of methylenetetrahydrofolate reductase (MTHFR) C677T may modulate the incidence and severity of COVID-19 [3]. Interestingly, a genetic link has been reported between risk for Alzheimer's disease and severe COVID-19 outcomes via the OAS1 gene [4]. Genetic polymorphisms of HLA genes [5, 6, 7] and vitamin K epoxide reductase complex subunit 1 (VKORC1) gene [8] are associated with severe

acute respiratory syndrome coronavirus (SARS-CoV) susceptibility, severity and mortality.

From a pathogenetic point of view, studies on the genetic variants of angiotensin converting enzyme (ACE) seems promising for further research on the topic, because the SARS-CoV gains entry into human host cells via an interaction with the ACE2 transmembrane receptor [9]. Accumulating evidence suggests that a subgroup of patients with severe COVID-19 might have a cytokine storm syndrome [10], which is caused by endothelial dysfunction in systemic inflammation, resulting in uncontrolled hyperthermia, tachypnea, tachycardia and hypotony [11]. It is vascular endothelial lesions and coagulopathy abnormalities that are the cause of frequent thromboembolic complications in COVID-19.

© Hutsaliuk K. M., Rossokha Z. I., Skalska N. Iu., Ulianova N. A., 2024

Given that the endothelium is present in all macrocirculatory and microcirculatory vessels, thromboembolic complications may develop in any vessel of any human organ. The ophthalmic manifestations of COVID-19 include narrowed retinal vessels, dilated retinal veins and proper coagulopathy and thromboembolic complications like cotton wool spots, vitreous hemorrhage, intraretinal hemorrhage, central retinal vein (CRV) prethrombosis, and CRV thrombosis [12]. To the best of our knowledge, however, there has been no report on the correlation between the retinal vascular changes, ACE gene variants and the severity of COVID-19 course. These data would allow predicting the course of the disease and development of extrapulmonary vascular complications, and preventing or managing these complications early.

The purpose of the study was to evaluate the relationship between ACE gene variants and the retinal changes as evidenced by fundoscopy in patients with various clinical courses of COVID-19.

Material and Methods

This was a prospected crossover non-controlled study. The study was conducted at the Infection Unit and Regional Eye Center of Volyn Regional Clinical Hospital

from October 2020 to December 2021. Ninety-four polymerase chain reaction (PCR) COVID-19-positive patients (188 eyes; age range, 42 to 82 years) admitted to the infection unit were included in the study. Patients with a prior history of retinal disease were excluded. Informed consent was obtained from all study subjects. The study was approved by the Bioethics Committee of Volyn Regional Clinical Hospital (Committee meeting minutes of October 29, 2020).

At the first phase of the study, we evaluated the distribution of ACE (rs4340) gene variants among patients. Thereafter, we investigated the features of the clinical course of COVID-19 in patients with different ACE gene variants.

Patients underwent general clinical examination of body systems (Table 1), and their vital signs and blood oxygen saturation levels were monitored from admission until discharge or death.

They were divided into 4 groups on the basis of the severity of the clinical course of COVID-19 (Table 1). Group 1 (n = 33) included patients with an extremely severe course of COVID-19 and signs of severe pneumonia and acute respiratory distress syndrome (ARDS) whose treatment included the use of artificial respiration. Group

Table 1. Clinical characteristics of groups of patients

Characteristic	Group 1 (n=33)	Group 2 (n=21)	Group 3 (n=25)	Group 4 (n=15)	P
Age (years)	64 (60–70.25)	68 (56.75–70.25)	61 (55.5–64.75)	57 (48–69.5)	0.172
Women (n, %)	17 (51.5)	14 (66.7)	13 (52)	8 (53.3)	0.700
Men (n, %)	16 (48.5)	7 (33.3)	12 (48)	7 (46.7)	
Pulmonary parenchymal lesions, M±SD (%)	68.3±4.9 ^{2,3,4}	51.2±5.8 ^{1,3,4}	40.7±4.5 ^{1,2,4}	30.3±3.5 ^{1,2,3}	<0.001
Blood oxygen saturation level (IQR), (%), N – 97–100%	87 (78–93) ³	94 (90.25–96.25)	96 (92–98) ¹	94 (87.25–96)	<0.001
Oxygen flow speed (IQR), l/min, used to maintain normal blood saturation	16 (11.5–20) ^{3,4}	12 (10–15)	8 (6–10) ¹	10 (8–14.25) ¹	<0.001
D-dimer level (IQR), N, up to 0.5 µg/ml	2,47 (0.91–2.987) ^{3,4}	1,1 (0.855–1.2) ⁴	0,53 (0.375–0.685) ¹	0,27 (0.17–0.345) ^{1,2}	<0.001
SBP (IQR), mmHg	130 (125–140)	130 (130–140)	130 (128.7–136.2)	130 (126.2–140)	0.695
DBP (IQR), mmHg	80 (80–90)	80 (80–90)	80 (80–81.25)	90 (80–90)	0.232
Heart rate (M±SD), beats/min	95.5±19.4	92.2±13.5	85.7±14.6	93.2±12.2	0.146
Respiratory rate (IQR), breaths/min	26 (23,5–32) ³	24 (24–26)	22 (19,5–24) ¹	24 (22–26)	0.001
Comorbidity: hypertensive heart disease (n, %)	10 (30.3)	4 (19)	10 (40)	5 (33.3)	0.494
Comorbidity: type1 or type 2 diabetes mellitus (n, %)	7 (21.2)	3 (14.3)	1 (4)	0 (0)	0.092

Note: P, significance of difference; n, number; SAT, systolic blood pressure; DAT, diastolic blood pressure; N, norm; 1, significant difference from group 1; 2, significant difference from group 2; 3, significant difference from group 3; 4, significant difference from group 4

2 (n = 21) included patients with a severe course of COVID-19 and signs of severe pneumonia, plus one of the following: respiratory rate ≥ 30 breaths/min, severe respiratory distress or SpO₂ <90% on room air. Group 3 (n = 25) included patients with a moderate course of COVID-19 without signs of severe pneumonia, SpO₂ $\geq 90\%$, and decompensated comorbidity. Group 4 (n = 15) included patients with a moderate course of COVID-19 without signs of severe pneumonia, SpO₂ $\geq 90\%$, and well-compensated comorbidity [13, 14].

Fundus images were obtained with a handheld fundus camera (Pictor Plus Fundus Camera or VistaView, Volk Optical, Mentor, OH). A photograph of the central retina of each eye was taken. In addition, a detailed photograph of retinal changes, if any, was taken. Thromboembolic complications (e.g., CRV thrombosis) were classified as per the 1990 Katznelson classification which includes, e.g., prethrombosis (an initial stage of CRV thrombosis with stasis of retinal venal circulation, tortuous retinal veins, and sometimes with papilledema).

A molecular and genetic study of ACE gene (rs4340) variants was carried out using allele-specific PCR at the Reference Centre for Molecular Diagnostic of Public Health Ministry of Ukraine [15]. Blood samples were collected and transported to the above facility as per the guidelines on the transportation of biological materials (Decree of the Health Ministry of Ukraine No.662 of July 30, 2013).

The normal distribution of quantitative data was tested with the Shapiro-Wilk test. Quantitative data are reported as mean plus or minus standard deviation (SD) when normally distributed and median (interquartile range (IQR)) when not. When comparing results between groups, analysis of variance or non-parametric Kruskal-Wallis tests were used. Dunn's test was used as a post hoc test. The chi square test was used for group comparison in the presence of comorbidity.

Qualitative data are reported as frequency (percentage) and 95% confidence interval (95% CI), if required. When comparing results between groups, analysis of variance was used for normally distributed quantitative variables, Kruskal-Wallis tests, for non-normally distributed quantitative variables, and chi square test, for qualitative variables. Dunn's test was used as a post hoc test after Kruskal-Wallis test. Bonferroni correction was applied to account for multiple comparisons.

To assess quantitatively the effects of independent variables on the risk of clinically significant retinal changes, logistic regression models were developed and analyzed. A receiver operating characteristic (ROC) curve was generated using the best fit model. Area under ROC curve (AUC) and 95% CI were calculated. Odds ratio (OR) and 95% CI were used to assess the relationships between the risk of clinically significant retinal changes and independent variables. The level of significance $p \leq 0.05$ was assumed.

Results

Among the analyzed individuals, 28 (29.6%) were found to have the II genotype, 47 (50.5%) had the ID genotype, and 19 (19.9%) had the DD genotype of the ACE. At the next phase of the study, we evaluated the clinical course of COVID-19 in patients with different ACE genotypes. No significant difference was found among groups of patients with the II, ID and DD genotypes with respect to respiratory system characteristics. In addition, there was no significant difference with respect to D-dimer level. It is important that no significant difference was found among groups of patients with the II, ID and DD genotypes with respect to the distribution of comorbidities (Table 2).

There was, however, a statistically significant difference among these groups with respect to the retinal changes in COVID-19. Generally, the following changes in the retina and other portions of the eye were found during eye examination in these patients: cotton wool spots, narrowed retinal vessels, vitreous hemorrhage, retinal hemorrhage, and petechial hemorrhage, central or branch retinal vein prethrombosis, central or branch retinal vein thrombosis, and tortuous and dilated retinal venules. Vitreous hemorrhage, central or branch retinal vein prethrombosis and central or branch retinal vein thrombosis were considered clinically significant changes (i.e., changes accompanied by significantly reduced vision). Cotton wool spots, narrowed retinal vessels, vitreous hemorrhage, retinal hemorrhage, and petechial hemorrhage, and tortuous and dilated retinal venules were considered clinically insignificant changes.

There were significant differences among groups of patients of different ACE genotypes with respect to the structure and frequency of the retinal changes as evidenced by fundoscopy (Table 3).

Particularly, there was a significant difference ($p = 0.008$) among these groups with respect to the frequency distribution of the retinal changes. There was an increase ($p < 0.001$) in the risk of clinically significant retinal changes in patients with the DD genotype (36.8%) compared to patients with the II genotype (0%) and those with the ID genotype (2.1%) ($p < 0.05$, as assessed by pairwise comparison with Bonferroni correction). No significant difference was, however, found among groups of COVID-19 patients of different ACE genotypes with respect to the distribution of particular retinal changes. There was no significant difference ($p = 0.960$) among these groups with respect to the severity of disease course.

We also assessed the risk of developing clinically significant retinal changes depending on the ACE genotype (Table 4). There was a reduction in the risk of clinically significant retinal changes in patients with the II of ID genotype compared to the DD genotype (OR = 0.023, 95% CI 0.003–0.21).

ROC curve of the model for predicting the risk of clinically significant retinal changes in COVID-19 patients depending on the ACE genotype is presented in

Table 2. Clinical characteristics of groups of patients depending on the ACE gene variant

Characteristic	Group 1 with ACE genotype II (n=28)	Group 2 with ACE genotype ID (n=47)	Group 3 with ACE genotype DD (n=19)	P
Age (years)	63.5 (55–70)	64 (57.75–70)	61 (56.25–70.75)	0.831
Pulmonary parenchymal lesions, M±SD (%)	50.6±15.5	50.9±14.3	52.2±17	0.934
Blood oxygen saturation level (%) (IQR)	92.5 (84–96.5)	92 (88.25–96)	93 (88.25–96.75)	0.851
Oxygen flow speed, l/min, used to maintain normal blood saturation (IQR)	11 (8–14.5)	12 (8–17.75)	10 (8.5–16)	0.726
SBP (IQR), mmHg	130 (125–140)	130 (125–140)	130 (130–140)	0.396
DBP (IQR), mmHg	80 (80–90)	80 (80–90)	80 (80–90)	0.695
Heart rate (M±SD), beats/min	91±17.5	92.7±16.2	90.7±14.6	0.873
Respiratory rate, breaths/min M±SD	24.2±4.4	24.3±4.1	25.1±4.7	0.765
D-dimer level (IQR), N, up to 0.5 µg/ml	0.66 (0.34–1.18)	0.79 (0.31–2.22)	1.09 (0.43–2.28)	0.380
Women (n, %)	16 (57.1)	25 (53.2)	11 (57.9)	0.916
Men (n, %)	12 (42.9)	22 (46.8)	8 (42.1)	
Comorbidity: type 1 or type 2 diabetes mellitus (n, %)	5 (17.9)	4 (8.5)	2 (10.5)	0.469
Comorbidity: hypertensive heart disease (n, %)	9 (32.1)	15 (31.9)	5 (26.3)	0.891

Note: DAT, diastolic blood pressure; N, norm; P, significance of difference; n, number; SAT, systolic blood pressure

Table 3. Characteristics of retinal changes in patients with COVID-19 depending on the ACE gene variant

Characteristic		Count (%)			P
		Group 1 (ACE genotype II), (n=28)	Group 2 (ACE genotype ID), (n=47)	Group 3 (ACE genotype DD), (n=19)	
Retinal changes	No retinal changes	18 (64.3) ³	30 (63.8)	8 (42.1) ¹	0.008
	cotton wool spots	3 (10.7)	5 (10.6)	1 (5.3)	
	narrowed retinal vessels	3 (10.7)	2 (4.3)	0 (0.0)	
	vitreous hemorrhage	0 (0.0)	0 (0.0)	2 (10.5)	
	petechial and retinal hemorrhage	2 (7.1)	5 (10.6)	3 (15.8)	
	CRV prethrombosis	0 (0.0)	0 (0.0)	1 (5.3)	
	CRV thrombosis	0 (0.0)	1 (2.1)	4 (21.1)	
	dilated and tortuous retinal vessels	2 (7.1)	4 (8.5)	0 (0.0)	
Clinically significant retinal changes	hi	28 (100.0) ³	46 (97.9) ³	12 (63.2) ^{1,2}	<0.001
	tak	0 (0.0)	1 (2.1)	7 (36.8)	
Severity group	1	9 (32.1)	16 (34.0)	8 (42.1)	0.960
	2	7 (25.0)	11 (23.4)	3 (15.8)	
	3	7 (25.0)	12 (25.5)	6 (31.6)	
	4	5 (17.9)	8 (17.0)	2 (10.5)	

Table 4. Association between the ACE gene variant and risk of clinically significant retinal changes in patients with COVID-19

Independent variable		Model coefficient, $b \pm m$	Significance of odds ratio (OR) difference from 1, p	Odds ratio (OR) (95% CI)
ACE	DD	Reference		
	II+ID	-3.76 \pm 1.11	0.001	0.023 (0.003–0.21)

Note: ACE, angiotensin-converting enzyme; CI, confidence interval

Fig. 1. An AUC of 0.87 (95% CI, 0.78–0.93) indicates a strong correlation between the ACE genotype and the development of clinically significant retinal changes in COVID-19 patients (a sensitivity of 87.5% (95% CI, 47.3%–99.7% and specificity of 86.0% (95% CI, 76.9%–92.6%)).

Discussion

Under conditions of the COVID-19 pandemic, the management of chronic retinal disorders has some specific considerations [16]. It has been demonstrated that (1) the course of COVID-19 and the presence of complications in COVID-19 patients very much depend on expressions of variants of multiple genes and (2) molecular and genetic studies may contribute to the alleviation and prevention of COVID-19 complications (e.g., ophthalmic complications of the disease). To the best of our knowledge, the current study is the first to consider ACE gene variants not only in the context of their relationships with the severity of COVID-19, but in the context of their relationships with the risk of vascular complications. We believe that these correlations seem reasonable given that the ACE2 receptors are prevalent in the parenchyma of lungs and kidneys and vascular endothelium [10, 11]. Previously, we have found a statistically significant association between the severity of COVID-19 and the severity and diversity of retinal changes [13]. This prompted us to search for the relationships between the ACE gene variants and the presence of retinal changes (as a manifestation of extrapulmonary vascular complications) in patients with COVID-19, and the search was successful.

From a pathogenetic point of view, the ACE facilitates the conversion of angiotensin I to angiotensin II, a potent vasoconstrictor which increases blood pressure [17]. ACE2 acts as the host cell receptor for SARS-CoV [9] and can be found in multiple cells and tissues (e.g., retinal cells [18, 19] and the vascular endothelium [10, 11]).

Woods and colleagues [20] considered the effects of the ACE gene variants on the vasoconstriction and elevated blood pressure. They reported that the D allele of the ACE I/D polymorphism is associated with elevated levels of serum and tissue ACE, increased production of the vasopressor angiotensin II and a reduction in the half-life of the vasodilator bradykinin. The insertion/deletion polymorphism accounted for 47% of the total phenotypic variance of serum ACE, showing that the ACE gene locus is the major locus that determines serum

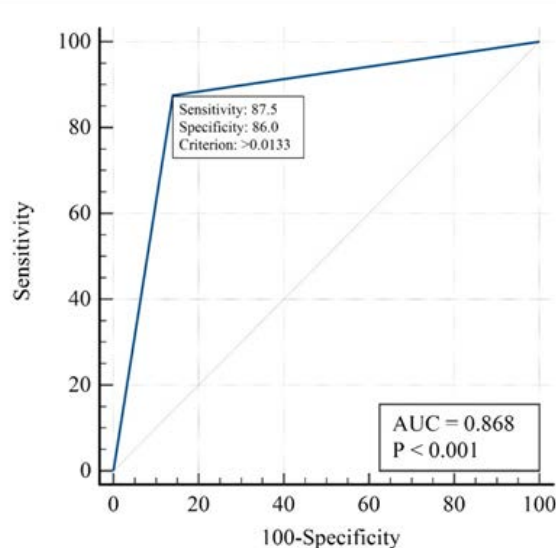


Fig. 1. ROC curve of the model for predicting the risk of clinically significant retinal changes in COVID-19 patients with the ACE DD genotype

ACE concentration [21]. While the highest ACE serum concentration was seen in the DD group (nearly 1.5 times of that of ID and II genotypes, respectively), it was the lowest in the II group [22]. The frequency of the genotype DD was higher than the frequencies of genotypes ID and II in patients with essential hypertension (EH), but not in the controls [23]. ACE gene D allele was associated with an overall higher EH susceptibility [24, 25]. DD genotype was significantly associated with the risk of acute ischemic stroke as a consequence of high blood pressure [26]. The progression of cerebral microbleeds over 2 years was greater in the ACE DD carriers compared with the combined II/ID carriers [27]. While considering the above data in the context of the detection of clinically significant retinal changes in COVID-19, the possible mechanism of these changes consists in the action of the ACE DD genotype as a direct vasoconstrictor via activation of angiotensin II. As a result, the conditions are created for the maximal narrowing of vessels, an increase in systemic blood pressure and maximal tissue hypoxia throughout the body (e.g., in the retina). It should be noted that vasoconstriction causes retinal tissue hypoxia and edema. Retinal edema, in its turn, is a factor of retinal tissue lesions, thus leading to functional impairment [28]. The

above mechanism is believed to promote the development of CRV prethrombosis, CRV thrombosis and vitreous hemorrhage.

As it is mentioned above, ACE2 acts as the host cell receptor for SARS-CoV [9], and SARS-CoV-2 infects the human host by attaching to the ACE2 and CD147 (basigin) receptors in some human cells (e.g., retinal cells) [18]. It has been reported that retinal cells (e.g., Müller cells, ganglion cells, retinal pigment epithelial (RPE) cells, retinal vascular cells) have cell receptors (ACE, ACE2 receptors, prorenin receptors and renin-angiotensin receptors) for binding to various components of the renin-angiotensin system [18]. Particularly, it has been reported on the presence of ACE/ACE2 receptors in organelles of RPE cells and retinal ganglion cells (human induced pluripotent stem cell-derived retinal organoids) which were found to be susceptible to infection in vitro with SARS-CoV-2 pseudovirus [29]. Interestingly, ACE/ACE2 expression was found to increase along the pathway from the cornea to the retina, and today this is considered as another potential route of virus spread to the deep structures of the retina, optic nerve and visual pathway [19]. Both ACE-2 and protein transmembrane serine protease 2 (TMPRSS2) are highly expressed in the human retina, and a recent case series of 3 patients discovered S and N proteins by immunofluorescence microscopy within retinal vasculae endothelial cells, presumably containing viral particles [30]. It is likely that such tropism of the virus to retinal cells explains the presence of statistically significant difference in the distribution of retinal changes among groups of patients with different ACE gene variants.

Therefore, we believe that all the above data may explain this diversity in retinal changes in COVID-19. An additional factor that facilitates significant retinal changes is increased activity of ACE in patients with ACE genotype DD, which increases vasospasm, leading to tissue hypoxia.

Conclusion

The risk of clinically significant retinal changes is higher in COVID-19 patients with ACE genotype DD than in those with genotype II or ID ($p < 0.001$).

References

- Kim Y-C, Jeong B-H. Strong correlation between the case fatality rate of COVID-19 and the rs6598045 single nucleotide polymorphism (SNP) of the interferon-induced transmembrane protein 3 (IFITM3) gene at the population-level. *Genes (Basel)* [Internet]. 2020;12(1):42. <http://dx.doi.org/10.3390/genes12010042>
- Aladawy SA, Adel LA, Abdel Salam SA, Raafat RH, Khattab MA. Polymorphism in promotor region of IL6 gene as a predictor for severity in COVID -19 patients. *Egypt J Immunol* [Internet]. 2022;29(2):1–9. <http://dx.doi.org/10.55133/eji.290201>
- Ponti G, Pastorino L, Manfredini M, Ozben T, Oliva G, Kaleci S, et al. COVID-19 spreading across world correlates with C677T allele of the methylenetetrahydrofolate reductase (MTHFR) gene prevalence. *J Clin Lab Anal* [Internet]. 2021;35(7). <http://dx.doi.org/10.1002/jcla.23798>
- Magusali N, Graham AC, Piers TM, Panichnantakul P, Yaman U, Shoai M, et al. A genetic link between risk for Alzheimer's disease and severe COVID-19 outcomes via the OAS1 gene. *Brain* [Internet]. 2021;144(12):3727–41. <http://dx.doi.org/10.1093/brain/awab337>
- Deb P, Zannat K-E, Talukder S, Bhuiyan AH, Jilani MSA, Saif-Ur-Rahman KM. Association of HLA gene polymorphism with susceptibility, severity, and mortality of COVID-19: A systematic review. *HLA* [Internet]. 2022;99(4):281–312. <http://dx.doi.org/10.1111/tan.14560>
- Tomita Y, Ikeda T, Sato R, Sakagami T. Association between HLA gene polymorphisms and mortality of COVID-19: An in silico analysis. *Immun Inflamm Dis* [Internet]. 2020;8(4):684–94. <http://dx.doi.org/10.1002/iid3.358>
- Amoroso A, Magistroni P, Vespasiano F, Bella A, Bellino S, Puoti F, et al. HLA and AB0 polymorphisms may influence SARS-CoV-2 infection and COVID-19 severity. *Transplantation* [Internet]. 2021;105(1):193–200. <http://dx.doi.org/10.1097/tp.0000000000003507>
- Janssen R, Walk J. Vitamin K epoxide reductase complex subunit 1 (VKORC1) gene polymorphism as determinant of differences in Covid-19-related disease severity. *Med Hypotheses* [Internet]. 2020;144(110218):110218. <http://dx.doi.org/10.1016/j.mehy.2020.110218>
- Zhou P, Yang X-L, Wang X-G, Hu B, Zhang L, Zhang W, et al. A pneumonia outbreak associated with a new coronavirus of probable bat origin. *Nature* [Internet]. 2020;579(7798):270–3. <http://dx.doi.org/10.1038/s41586-020-2012-7>
- Mehta P, McAuley DF, Brown M, Sanchez E, Tattersall RS, Manson JJ. COVID-19: consider cytokine storm syndromes and immunosuppression. *Lancet* [Internet]. 2020;395(10229):1033–4. [http://dx.doi.org/10.1016/s0140-6736\(20\)30628-0](http://dx.doi.org/10.1016/s0140-6736(20)30628-0)
- Kumar M, Al Khodor S. Pathophysiology and treatment strategies for COVID-19. *J Transl Med* [Internet]. 2020;18(1). <http://dx.doi.org/10.1186/s12967-020-02520-8>
- Invernizzi A, Torre A, Parrulli S, Zicarelli F, Schiuma M, Colombo V, et al. Retinal findings in patients with COVID-19: Results from the SERPICO-19 study. *EClinicalMedicine* [Internet]. 2020;27(100550):100550. <http://dx.doi.org/10.1016/j.eclinm.2020.100550>
- Order of the Ministry of Health of Ukraine of March 28, 2020 No. 722, <https://www.dec.gov.ua/mtd/koronavirusna-hvoroba-2019-covid-19/>
- Clinical management of patients with COVID-19 "live" clinical guideline from 2021, <https://www.dec.gov.ua/mtd/koronavirusna-hvoroba-2019-covid-19/>
- Rossokha ZI, Fishchuk LYe, Pokhylko VI, Cherniavska YuI, Tsvirenko SM, Kovtun SI, et al. The deletion variant of the CCR5 gene (rs333) but not the ACE gene (rs4340) is associated with long-term respiratory support in patients with COVID-19 pneumonia. *Ukrainian Medical Journal*. 2020;6(140):1-5. 10.32471/umj.1680-3051.140.195935.
- Management of patients with chronic retinal diseases in the current conditions of the COVID-19 pandemic in the world and in Ukraine. *J Ophthalmol (Ukraine)* [Internet]. 2021;91(2):82–4. <http://dx.doi.org/10.31288/oftalmolzh202128284>
- Aghsaefard Z, Alizadeh R. The role of angiotensin-converting enzyme in immunity: Shedding light on experimental findings. *Endocr Metab Immune Disord Drug Targets* [Internet]. 2022;22(1):6–14. <http://dx.doi.org/10.2174/1871530321666210212144511>

18. Li Y-P, Ma Y, Wang N, Jin Z-B. Eyes on coronavirus. *Stem Cell Res* [Internet]. 2021;51(102200):102200. Available from: <http://dx.doi.org/10.1016/j.scr.2021.102200>
19. Hill JM, Clement C, Arceneaux L, Lukiw WJ. Angiotensin converting enzyme 2 (ACE2) expression in the aged brain and visual system. *J Aging Sci*. 2021;9(Suppl 7).
20. Woods DR, Humphries SE, Montgomery HE. The ACE I/D polymorphism and human physical performance. *Trends Endocrinol Metab* [Internet]. 2000;11(10):416–20. [http://dx.doi.org/10.1016/s1043-2760\(00\)00310-6](http://dx.doi.org/10.1016/s1043-2760(00)00310-6)
21. Rigat B, Hubert C, Alhenc-Gelas F, Cambien F, Corvol P, Soubrier F. An insertion/deletion polymorphism in the angiotensin I-converting enzyme gene accounting for half the variance of serum enzyme levels. *J Clin Invest* [Internet]. 1990;86(4):1343–6. <http://dx.doi.org/10.1172/jci114844>
22. Mohammadi F, Shahabi P, Zabani S, AA Z. Insertion/Deletion Gene Polymorphism and Serum Level of Angiotensin Converting Enzyme. *TANAFOS (Respiration)*. 2008; 7(2):18-22.
23. Patel DD, Parchwani DN, Dikshit N, Parchwani T. Analysis of the pattern, alliance and risk of rs1799752 (ACE I/D polymorphism) with essential hypertension. *Indian J Clin Biochem* [Internet]. 2022;37(1):18–28. <http://dx.doi.org/10.1007/s12291-020-00927-0>
24. Pinheiro DS, Santos RS, Jardim PCBV, Silva EG, Reis AAS, Pedrino GR, et al. The combination of ACE I/D and ACE2 G8790A polymorphisms reveals susceptibility to hypertension: A genetic association study in Brazilian patients. *PLoS One* [Internet]. 2019;14(8):e0221248. <http://dx.doi.org/10.1371/journal.pone.0221248>
25. Liu M, Yi J, Tang W. Association between angiotensin converting enzyme gene polymorphism and essential hypertension: A systematic review and meta-analysis. *J Renin Angiotensin Aldosterone Syst* [Internet]. 2021;22(1):147032032199507. <http://dx.doi.org/10.1177/1470320321995074>
26. Goyal A, Saluja A, Saraswathy KN, Bansal P, Dhamija RK. Role of ACE polymorphism in acute ischemic stroke. *Neurol India* [Internet]. 2021;69(5):1217–21. <http://dx.doi.org/10.4103/0028-3886.329586>
27. Yoon CW, Kim J, Suh YJ, Kim BC, Youn YC, Jeong JH, et al. Angiotensin-converting enzyme insertion/deletion gene polymorphism and the progression of cerebral microbleeds. *Front Neurol* [Internet]. 2023;14. <http://dx.doi.org/10.3389/fneur.2023.1230141>
28. Peretiahina D, Shakun K, Ulianov V, Ulianova N. The role of retinal plasticity in the formation of irreversible retinal deformations in age-related macular degeneration. *Curr Eye Res* [Internet]. 2022;47(7):1043–9. <http://dx.doi.org/10.1080/02713683.2022.2059810>
29. Ahmad Mulyadi Lai HI, Chou S-J, Chien Y, Tsai P-H, Chien C-S, Hsu C-C, et al. Expression of endogenous angiotensin-converting enzyme 2 in human induced pluripotent stem cell-derived retinal organoids. *Int J Mol Sci* [Internet]. 2021;22(3):1320. Available from: <http://dx.doi.org/10.3390/ijms22031320>
30. Hu K, Patel J, Swiston C, Patel BC. Ophthalmic Manifestations of Coronavirus (COVID-19). 2022 May 24. In: *StatPearls* [Internet]. Treasure Island (FL): StatPearls Publishing; 2024 Jan–. PMID: 32310553.

Acknowledgement: *We wish to thank V.G. Gur'ianov for his assistance in statistical analysis.*

Disclosures

Received 02.09.2023

Accepted 13.02.2024

Corresponding author: *Kateryna M. Hutsaliuk, Ophthalmologist, Regional Eye Center of Volyn Regional Clinical Hospital; Senior Lecturer, Department of General Pathology and Surgical Diseases, Medical School of the Lesya Ukrainka Volyn National University; Post-Graduate Student of the SI "The Filatov Institute of Eye Diseases and Tissue Therapy of the NAMS of Ukraine", Odesa, Ukraine, E-mail: galej_kamy@tdmu.edu.ua*

Author Contributions: *KMH: Conceptualization, Project Administration, Data Curation, Data Analysis and Interpretation, Writing – original draft; ZIR: Investigation, Data Analysis and Interpretation; NluS: Data Curation, Data Analysis and Interpretation, Writing – review & editing; NAU: Conceptualization, Project Administration, Data Curation, Data Analysis and Interpretation, Writing – review & editing*

Disclaimer: *The opinions presented in this article are those of the authors and do not necessarily represent those of their institutions.*

Funding: *No funding*

Conflict of interest: *The authors state that there are no conflicts of interest that might influence their opinion on the subject matter or materials described or discussed in this manuscript.*

Ethics Statement: *Appropriate informed consent was obtained from all subjects.*

This study included human participants, was approved by the local bioethics committee and adhered to the tenets of the Declaration of Helsinki. This study did not include animal experiments.

Abbreviations: *ACE, angiotensin converting enzyme; CRV, central retinal vein; DBP, diastolic blood pressure; HR, heart rate; PCR, polymerase chain reaction; RR, respiratory rate; SBP, systolic blood pressure*